



SOCIETY FOR ENDOCRINOLOGY ENDOCRINE EMERGENCY GUIDANCE

Emergency management of pituitary apoplexy in adult patients

**Stephanie E Baldeweg^{1,2}, Mark Vanderpump³, Will Drake⁴, Narendra Reddy⁵,
Andrew Markey⁶, Gordon T Plant^{1,2}, Michael Powell², Saurabh Sinha⁷, John Wass⁸
and the Society for Endocrinology Clinical Committee⁹**

¹Department of Endocrinology, University College Hospital, London, UK

²National Hospital for Neurology and Neurosurgery, London, UK

³Physicians' Clinic, London, UK

⁴Department of Endocrinology, St Bartholomew's Hospital, London, UK

⁵Endocrinology/General Medicine, University Hospitals Coventry and Warwickshire NHS Trust, University of Warwick, Coventry, UK

⁶The Lister Hospital, London, UK

⁷Royal Hallamshire Hospital, Sheffield, UK

⁸Department of Endocrinology, Oxford Centre for Diabetes Endocrinology and Metabolism, The Churchill, Oxford University, Oxford, UK

⁹The Society for Endocrinology, 22 Apex Court, Woodlands, Bradley Stoke, Bristol, UK

Correspondence
should be addressed
to S E Baldeweg
Email
stephanie.baldeweg@uclh.nhs.uk

Introduction

Classical pituitary apoplexy is a medical emergency and rapid replacement with hydrocortisone may be lifesaving. It is caused by haemorrhage and/or infarction of a tumour within the pituitary gland. A high index of clinical suspicion is essential to diagnose this condition as prompt management may be life and vision saving. This guideline aims to take the non-specialist through the initial phase of assessment and management.

Clinical presentation

The diagnosis of pituitary apoplexy is often delayed as ~80% of these patients will have no previous history of a pituitary problem and the clinical features mimic other more common neurological conditions.

- A diagnosis of pituitary apoplexy should be considered in all patients who have acute severe headache and any of the following:
 - patients in whom subarachnoid haemorrhage (SAH) and meningitis have been excluded

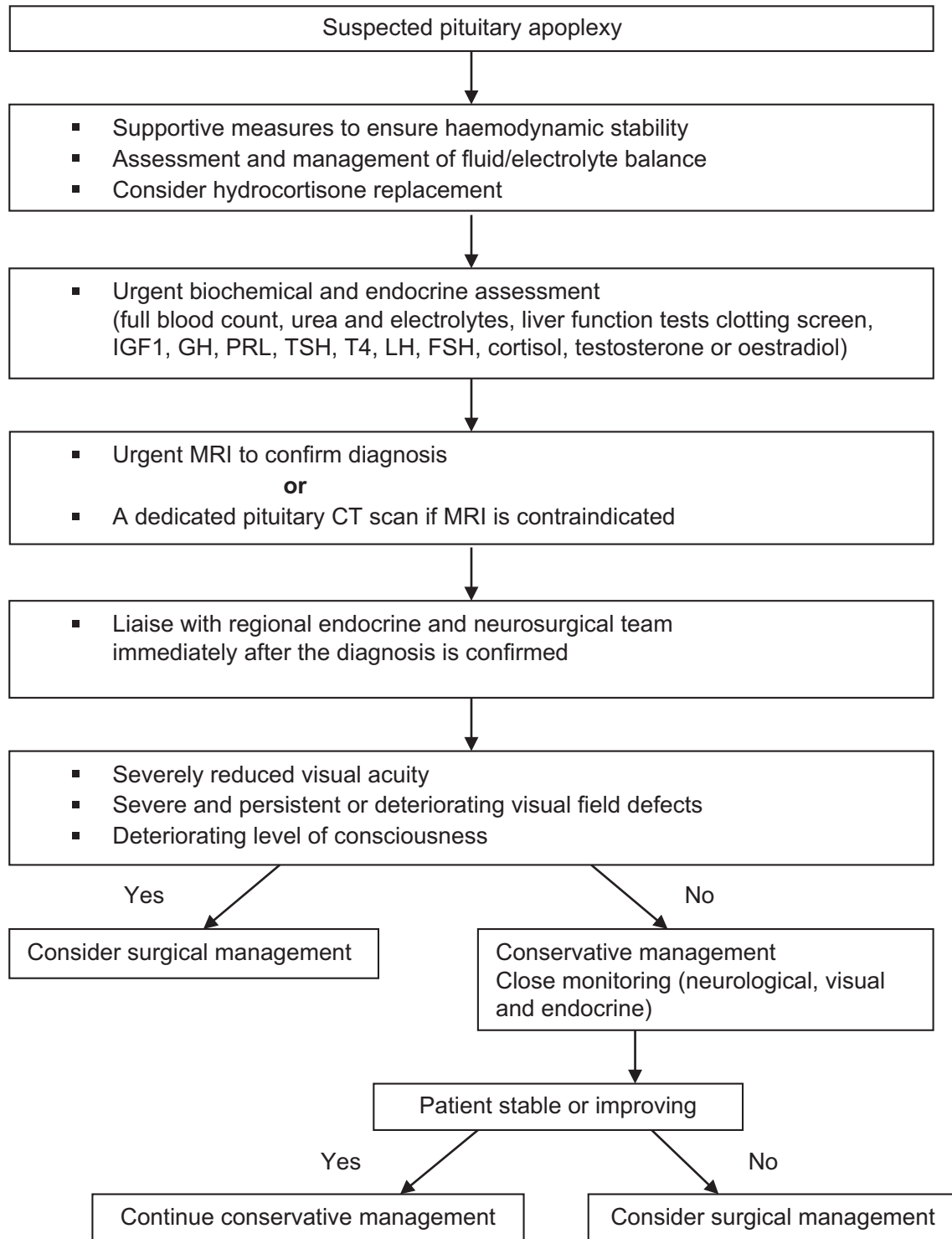
- patients with neuro-ophthalmic signs
- patients with pre-existing pituitary tumours

- Acute severe headache is the most common and earliest manifestation. Headache may be accompanied by nausea and vomiting
- Ocular palsies, most commonly a third nerve palsy, can occur due to involvement of the cavernous sinus
- Reduced visual acuity and visual field defects, most commonly a bi-temporal hemianopia, are due to optic chiasmal compression
- Fever, neck stiffness, photophobia or reduced consciousness (similar to signs/symptoms of SAH or meningitis) may occur

Precipitating factors

Hypertension, major surgery, especially coronary artery bypass grafting, dynamic testing of the pituitary gland, anticoagulation therapy, coagulopathies, pregnancy and head trauma.



**Figure 1**

Pituitary apoplexy emergency management summary.

Differential diagnosis

- SAH due to ruptured intracranial aneurysm or arteriovenous malformation
- Bacterial/viral meningitis
- Brainstem infarction
- Cavernous sinus thrombosis

Management

- Ensure haemodynamic stability through supportive measures
- Urgent bloods: urea and electrolytes, full blood count, renal and liver function tests, clotting profile
- Indications for empirical steroid therapy in patients with pituitary apoplexy are haemodynamic instability, altered consciousness level, reduced visual acuity and severe visual field defects. Steroid replacement is potentially lifesaving in these patients
- In adults, hydrocortisone 100 mg i.m. bolus followed by 50–100 mg six hourly by intramuscular injection or 100–200 mg as an intravenous bolus followed by 2–4 mg per hour by continuous i.v. infusion can be used
- Careful assessment of fluid and electrolyte balance
- Ideally, endocrine evaluation with blood samples for random serum cortisol, TSH, free T₄, prolactin, IGF1, LH, FSH, testosterone (men), oestradiol (women) for later analysis
- Bedside assessment of visual acuity and fields
- Further neuro-ophthalmic assessments can be undertaken when the patient is clinically stable
- CT brain (± LP) to exclude SAH and meningitis should be undertaken if not already done
- Magnetic resonance imaging (MRI) is the investigation of choice and has been shown to confirm the diagnosis in over 90% of patients. A pituitary CT is indicated if MRI is contraindicated or not possible
- Urgent referral to the joint neurosurgical/endocrine unit for definitive management

After emergency care: where should patients with pituitary apoplexy be managed?

Once the diagnosis has been confirmed, it is recommended that all patients be transferred once medically stabilised, following liaison and advice from the specialist neurosurgical/endocrine team, to the local neurosurgical/endocrine team as soon as possible. Neurosurgical high

dependency unit (HDU) facilities must be available. This team must have access to specialist endocrine and ophthalmological expertise. These patients should then be managed according to the Society for Endocrinology UK guidelines for the management of pituitary apoplexy (1).

Indications for surgery

Patients should first be stabilised medically with steroid replacement, if needed, before surgical intervention. Studies have shown significantly greater improvement in visual acuity and visual field defects in patients who had early surgery (within 8 days).

Surgical intervention should be considered in patients with:

- Severely reduced visual acuity
- Severe and persistent visual field defects
- Deteriorating level of consciousness

Long-term follow-up

All patients with pituitary apoplexy need follow-up by endocrine and neurosurgical teams. They require repeat assessment of pituitary and visual function, at 4–6 weeks. Thereafter, 6–12 monthly follow-up to optimise hormonal replacement and to monitor tumour progression/recurrence.

Summary

See Fig. 1 for an emergency management summary.

Pituitary apoplexy is a rare and potentially lethal endocrine emergency, characterised by acute severe headache, visual defects, and/or reduced consciousness.

The clinical presentation often mimics other more common neurological emergencies.

Prompt resuscitation and corticosteroid replacement may be lifesaving.

MRI scan is the investigation of choice.

Urgent discussion with the regional neurosurgical/endocrine team is essential.

Surgical intervention should be considered in patients with severe and persisting visual defects or in those with deteriorating level of consciousness after medical stabilisation and steroid replacement.

Acknowledgements

The authors would like to thank Senthil Rajasekaran and Marian Lanyon for their contributions to the UK Guidelines for the Management of Pituitary Apoplexy.



Disclaimer

The document should be considered as a guideline only; it is not intended to determine an absolute standard of medical care. The doctors concerned must make the management plan for an individual patient.

Reference

- 1 Rajasekaran S, Vanderpump M, Baldeweg S, Drake W, Reddy N, Lanyon M, Markey A, Plant G, Powell M, Sinha S, *et al.* UK guidelines for the management of pituitary apoplexy. *Clinical Endocrinology* 2011 **74** 9–20. (doi:10.1111/j.1365-2265.2010.03913.x)

Received in final form 3 August 2016

Accepted 3 August 2016

