

## RESEARCH

# Is thyroglobulin detection in fine-needle aspirates useful for the diagnosis of central neck metastatic papillary thyroid cancer?

Yuntao Song<sup>1</sup>, Jiaxin Wang<sup>1</sup>, Yanli Zhu<sup>2</sup>, Guohui Xu<sup>1</sup>, Tianxiao Wang<sup>1</sup> and Bin Zhang<sup>1</sup><sup>1</sup>Key Laboratory of Carcinogenesis and Translational Research, Ministry of Education/Beijing, Department of Head and Neck Surgery, Peking University Cancer Hospital and Institute, Beijing, China<sup>2</sup>Key Laboratory of Carcinogenesis and Translational Research, Ministry of Education/Beijing, Department of Pathology, Peking University Cancer Hospital and Institute, Beijing, ChinaCorrespondence should be addressed to B Zhang: [0065610719@bjmu.edu.cn](mailto:0065610719@bjmu.edu.cn)

## Abstract

**Objective:** The central neck lymph node (LN) status is important for the treatment strategy of papillary thyroid cancer (PTC), while the diagnosis is difficult. This study aims to evaluate the diagnostic value of fine-needle aspiration (FNA) and its washout thyroglobulin (FNA-Tg) detection in central neck LN metastasis.

**Methods:** Central neck LNs with FNA cytology (FNA-C) and FNA-Tg measurements from a tertiary hospital were included. Tg levels were correlated with histopathological or follow-up results. The diagnostic performance of FNA-C, FNA-Tg, and combining FNA-C and FNA-Tg for detecting LN metastasis was assessed.

**Results:** A total of 132 LNs in the central neck from 129 patients were studied. The median FNA-Tg concentration of 74 metastatic LNs was 552.5 ng/mL, whereas, in 58 benign LNs, the median Tg concentration was 0.1 ng/mL ( $P < 0.001$ ). Receiver operating characteristic analysis (area under the curve, 0.861) was used, and a cutoff value of 14.6 ng/mL was obtained. There was no significant increase in the diagnostic accuracy when FNA-Tg was used or combined with FNA-C, compared with FNA-C alone. The size, location of LNs, the presence of the ipsilateral thyroid gland, and Hashimoto's thyroiditis did not affect the incidence of misdiagnosis.

**Conclusions:** FNA-C is the gold standard for evaluating central neck metastasis in PTC patients. Measurement of Tg levels in FNA washout does not improve the diagnostic accuracy any further.

## Key Words

- ▶ papillary thyroid cancer
- ▶ level VI
- ▶ central neck
- ▶ fine-needle aspiration
- ▶ washout thyroglobulin measurement

Endocrine Connections  
(2022) 11, e220353

## Introduction

The incidence-based mortality rates of thyroid cancer continued to increase over the past few decades, with papillary thyroid cancer (PTC) being the most common histology (1). Recurrent or persistent metastasis of the neck lymph nodes (LNs) is the main cause of treatment failure (2). According to the stepwise dissemination of PTC cells through the lymphatic system, the central LN of the neck (level VI) is the most common region of metastasis compared to other parts (3, 4).

In PTC patients, the preoperative central LN state is critical in the surgical decision. In patients with central LN metastasis, the 2015 American Thyroid Association guidelines recommend total thyroidectomy with central neck dissection (CND), regardless of tumor size (5). Recently published randomized controlled trials found no benefit of prophylactic CND on locoregional or biochemical recurrence in patients with clinically free central LNs but confirmed a higher risk of permanent hypoparathyroidism

(6, 7, 8). For patients with tumors smaller than 1 cm, an active surveillance strategy is considered an ideal treatment option in the absence of LN metastasis or other high-risk features (9, 10, 11). Therefore, the accurate diagnosis of central neck LN involvement is crucial for optimizing treatment strategy.

Palpation of the central neck is difficult due to anatomical constraints. Radiological techniques such as ultrasound show poor performance in detecting central LN metastasis compared to that of the lateral neck (12), especially in the case of Hashimoto's thyroiditis (HT), in which reactive hyperplasia of LNs around the thyroid gland is often observed (13). Ultrasound-guided fine-needle aspiration (FNA) is the method of choice to confirm suspect LNs. Several studies have demonstrated that the addition of thyroglobulin (Tg) detection in FNA washout resulted in better accuracy (14). However, these reported findings mostly included lateral neck LNs. The diagnostic value of washout Tg in central neck FNA aspirates is debatable (5). A few systematic reviews displayed that false-positive Tg washout may occur, particularly in LNs in the central compartment when the thyroid gland is still present (15, 16). Therefore, we investigated the usefulness of FNA washout Tg in diagnosing central LN metastasis and addressing possible diagnostic dilemmas.

## Methods

### Study design

This is a retrospective chart review in a single tertiary care center. Ethics committee approval was obtained from the Institutional Review Board of the Peking University Cancer Hospital (No. 2020KT106). The informed consent from the patients was waived.

### Study population and FNA techniques

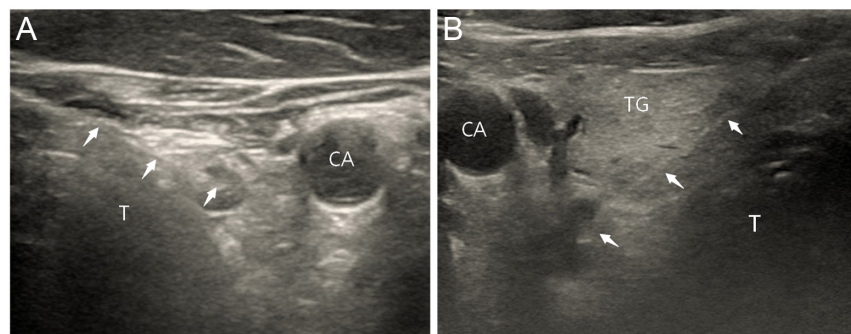
The institutional database was used to identify consecutive patients with FNA of suspicious central neck LNs with

cytology (FNA-C) and Tg washout (FNA-Tg) between September 2017 and March 2022. Patients with benign thyroid lesions or non-papillary carcinoma were excluded. All study patients had previously undergone radiologist-performed neck ultrasounds. Central neck compartments were examined concurrently with thyroid nodules workup or during follow-up after thyroidectomy. The central neck was bound superiorly by the hyoid bone, laterally by the carotid arteries, inferiorly by the innominate artery on the right, and the corresponding axial plane on the left (17). FNAs were performed for LNs with ultrasonographic features that indicated malignancy. Ultrasound findings that prompted an FNA were (i) microcalcification, (ii) loss of normal hilar architecture, and (iii) cystic change (12). The size of LN was not considered a criterion as long as FNA could be performed.

All FNAs were performed by a group of experienced head and neck surgeons using a high-resolution ultrasound scanner (M9; Mindray, Shenzhen, China). Pretracheal LNs and paratracheal LNs were aspirated directly without penetrating the thyroid (Fig. 1A). LNs at the lateral or dorsal side of the thyroid were biopsied with the needles through the gland (Fig. 1B). After the ipsilateral thyroid gland had been resected, the right paraesophageal lymph nodes hid behind the carotid artery, and the needle had to go through the scar tissue between the trachea and the artery to approach the target node, as we reported in previous article (18). A 23- or 25-gauge needle was used and connected to a 2 mL syringe. Each LN was aspirated once. The FNA technique and specimen processing approach were previously described in detail (19). There were no complications with the procedure.

The cytology results were divided into three categories: positive (malignancy or suspicious malignancy), negative (normal lymphocyte), and nondiagnostic (atypical cells or cellular paucity).

Two threshold values were used to assess the diagnostic performance of FNA-Tg: (i) 1 ng/mL, according to our previous research (19); (ii) The cutoff value obtained



**Figure 1**

(A) A paratracheal lymph node (0.6 × 0.4 cm) located on the caudal side of the thyroid gland was aspirated without penetrating the thyroid; (B) A parathyroid lymph node (0.9 × 0.6 cm) on the dorsal side of the thyroid were biopsied with the needles through the gland. CA, carotid artery; T, trachea; TG: thyroid gland; White arrow, needle tip in the target node and the needle path.

by receiver operating characteristic (ROC) analysis. Undetectable Tg in the washout fluid was reported as <0.04 ng/mL, which was considered 0.04 ng/mL. FNA-Tg values > 50,000 ng/mL were taken as 50,000 in the current study to facilitate statistical analysis.

The LNs were located by ultrasound. A pretracheal LN has its center on the ventral side of the plane of the anterior wall of the trachea, and a paratracheal LN was located at the caudal side of the lower pole of the thyroid gland and by the side of the trachea. If there was thyroid tissue between LN and the trachea, the LN was defined as parathyroid. HT can be diagnosed by ultrasound if it exposes diffused thyroid enlargement with abundant blood flow and elevated serum thyroglobulin antibody or be confirmed by postoperative histopathology.

For patients treated initially with cytologically negative central LN, a thyroidectomy with prophylactic CND was suggested if the primary tumor size was larger than 1 cm. Active surveillance or thermal ablation was also an alternative treatment for microcarcinoma in the absence of a high-risk location (e.g. a tumor adjacent to the recurrent laryngeal nerve), leaving the negative LNs observed. For post-thyroidectomy patients with cytologically negative results, the LNs were not resected and were clinically followed up for at least 6 months. A therapeutic CND was performed for patients with cytologically positive central LN, combined with total thyroidectomy or lateral neck dissection if necessary. The final pathological examination result was used as the gold standard. A benign LN was also defined as one

without progression at the ultrasound follow-up with a stable serum Tg level. The treatment process of patients is demonstrated in Fig. 2.

Statistical analysis

Statistical analysis was performed using SPSS for Windows (version 22.0, Chicago, IL, USA). ROC curves were constructed and the cutoff value was determined as the points in the upper left-hand corner. Sensitivity, specificity, positive predictive value (PPV), negative predictive value (NPV), and accuracy of FNA-Tg in different categories of patients were calculated. The McNemar test for statistical significance was used to compare the accuracy of diagnosis between either FNA-Tg threshold values or FNA-C alone. The chi-square test was performed to evaluate the differences in the incidence of false-negative or false-positive FNA-Tg results by each clinical feature. A P value of <0.05 was considered statistically significant.

Results

A total of 133 PTC patients underwent 136 FNAs in the central neck compartment. Four patients were lost to follow-up and were excluded. Table 1 summarizes the demographic and clinical details of the remaining 129 patients and 132 LNs.

All patients were examined for FNA-C and FNA-Tg. Cytology revealed malignant (n = 59, 45%), suspicious malignant (n = 5, 4%), benign (n = 64, 48%), and

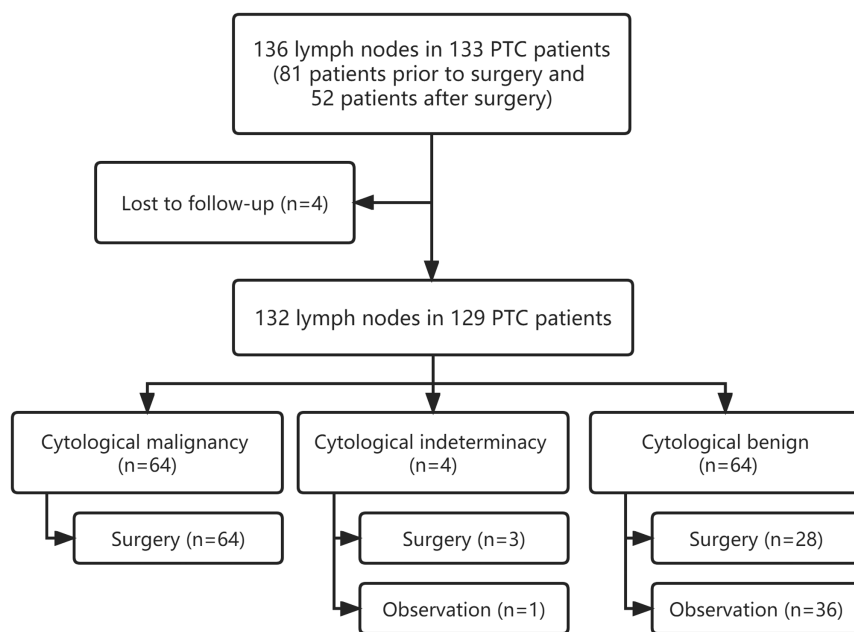


Figure 2 Diagram for patient selection and treatment process.

**Table 1** Summary of study cohort.

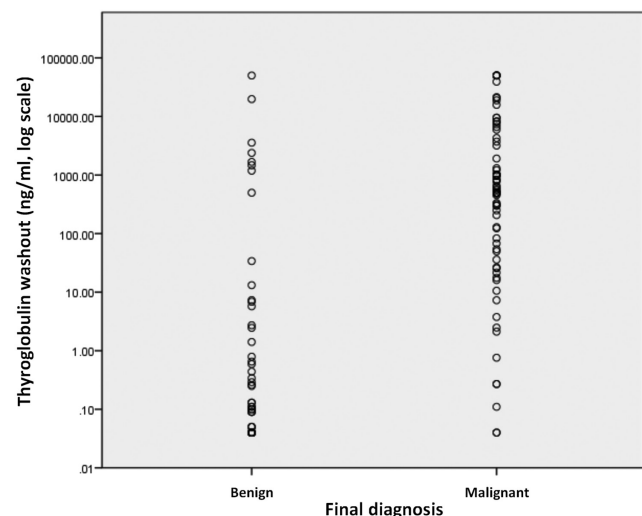
Parameter	Count (N = 129 patients)
Age, years, median (IQR)	37 (31–48)
Sex, count (%)	
Female	104 (81)
Male	25 (19)
Timing of FNA (%)	
Prior to surgery	78 (60)
After surgery	51 (40)
Hashimoto's thyroiditis (%)	58 (45)
Parameter	Count (N = 132 lymph nodes)
Lymph node location, count (%)	
Pretracheal	25 (19)
Paratracheal	100 (76)
Parathyroid	7 (5)
Ipsilateral thyroid status <sup>a</sup> (%)	
Intact	92 (70)
Partial residue	8 (6)
Absence	32 (24)
Maximum diameter of lymph node, cm, median (IQR)	0.8 (0.6–1.0)
Lymph node ultrasound characteristics (%)	
Hypoechoogenicity or unbalanced inner echo	88 (67)
Calcification	31 (23)
Cystic changes	13 (10)
FNA cytology, count (%)	
Malignant	59 (45)
Suspicious malignant	5 (4)
Nondiagnostic	4 (3)
Benign	64 (48)
Tg concentration in FNA washout, ng/mL, median (IQR)	34.9 (0.1–1108.0)

<sup>a</sup>Evaluated by ultrasound.

nondiagnostic ( $n = 4$ , 3%). Three of the four LNs with cellular atypia were resected, and one was found to harbor metastasis. Overall, 95 (72%) LNs were resected, and 74 metastatic LNs were confirmed by formal pathological examination. Fourteen patients with microcarcinoma underwent microwave ablation on the primary tumor. The other 23 cases with cytological negative LNs had a median non-operative follow-up of 14 (6–57) months and showed no signs of recurrence.

Tg concentration in the washout fluid in the whole cohort ranged between 0.04 and 50,000 ng/mL (median, interquartile range (IQR): 34.9, 0.1–1009.5), which are the lower and upper limits for FNA-Tg values considered in the laboratory of the the Peking University Cancer Hospital. FNA-Tg concentration was significantly higher in LNs that harbored metastasis than those that did not (median (IQR): 522.5 (52.9–3856.5) vs 0.1 (0.04–2.53) ng/mL, respectively;  $P < 0.001$ ; Fig. 3).

The distribution of FNA-Tg levels according to the final diagnosis of each specimen was reviewed. Receiver operator characteristic (ROC) analysis was conducted to assess the appropriate threshold value of FNA-Tg levels in



**Figure 3**

Scatter plot depicting the thyroglobulin washout concentrations detected from benign and malignant lymph nodes.

all cases. The area under the ROC curve is 0.861 ( $P < 0.001$ , 95% CI 0.789–0.933, Fig. 4). The best cutoff value of Tg for the diagnosis of central LN metastasis was 14.6 ng/mL.

The diagnostic performance of FNA-Tg was evaluated using two threshold values: 14.6 and 1 ng/mL. For cytological results, LNs with reports documenting metastases from thyroid carcinoma, suspicious metastases, and reports including the mention of 'atypical epithelial cells' were considered positive. Negative diagnoses included normal lymphocytes and insufficient material. Combining FNA-C with FNA-Tg (FNA-C+Tg), the interpretation was considered positive if either criterion included was positive. The sensitivity, specificity, PPV, NPV, and accuracy of FNA-Tg in different threshold values, FNA-C, and their combinations were assessed (Table 2).

With the McNemar test for statistical significance, the accuracy of detecting metastatic LNs with FNA-Tg and FNA-C+Tg was compared with the accuracy of diagnosis relying on FNA-C alone. The two different threshold values were analyzed separately. There was no significant increase in the accuracy when FNA-Tg was used or combined with FNA-C compared with FNA-C alone (Table 2).

Using 14.6 ng/mL as the threshold value of FNA-Tg levels, 15% ( $n = 20/132$ ) of all FNA Tg washouts failed to make the correct diagnosis. False-negative FNA-Tg was found in 11 LNs, all confirmed by postoperative pathology. False-positive FNA-Tg was found in nine LNs, five were resected, and others were put under observation. One of the

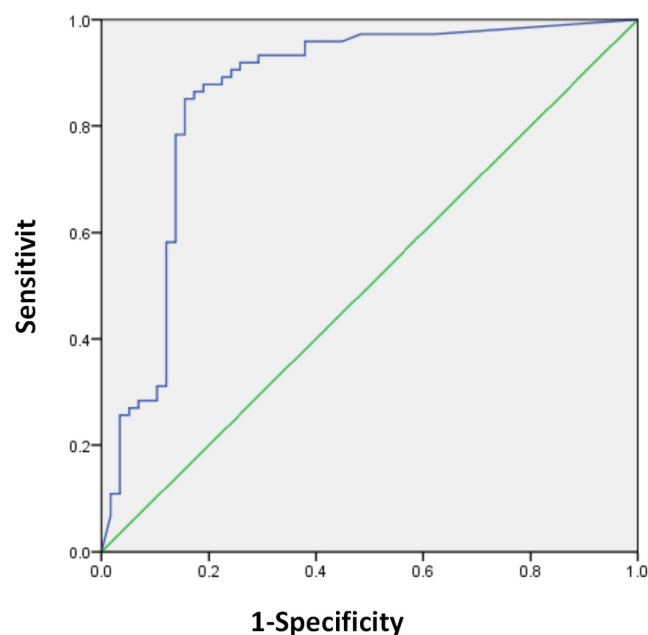
false-positive LNs was revealed to be parathyroid adenoma by histopathology, another was normal residual thyroid tissue, and the rest three were normal LNs. Four LNs were followed up for 12, 15, 19, and 50 months, respectively, with no progress. Clinicopathologic risk factors that may be led to misdiagnosis are listed in Table 3. In the univariate analysis, LN size, location, ipsilateral thyroid status, or the coexistence of HT were not significantly correlated with false-positive, false-negative, or misdiagnosed FNA-Tg results.

## Discussion

The metastatic status of LNs in neck level VI is important for the treatment decision of PTC. A clinically suspected central LN can lead a patient suitable for active surveillance to surgery or to suffer the complications of total thyroidectomy with central-compartment neck dissection unless it can be proved preoperatively that it is not metastatic.

Since the use of FNA-Tg for detecting thyroid cancer metastasis was first described by Pacini *et al.* in 1992 (20), many studies have reported that this method has high sensitivity and specificity for diagnosing LN metastasis (15, 16). However, to the best of our knowledge, few studies have specifically focused on the diagnostic value of FNA-Tg in the central neck. Our previous study depicted that in the lateral cervical LNs, the diagnostic accuracy of FNA-C plus Tg was significantly higher than that of FNA-C alone (19), which was in agreement with other studies. Nonetheless, in this study, which only included central LNs, we found no benefit of adding washout Tg measurement to FNA-C.

The presence of thyroid was supposed to affect the accuracy of FNA-Tg. Tg is stored in the lumen of thyroid follicles, and the level of washout Tg of the lateral neck LNs may be higher if the patient has retained the thyroid gland because the thyroid is the main source of serum Tg (21, 22). For central LNs closer to the thyroid gland, the interference may be greater and more complex. The needles may puncture the gland or the vessels around it causing contamination of the washout by the released Tg. The threshold value of FNA-Tg has not yet been well established, 1 ng/mL is the optimal cutoff value validated by the largest published study (23) and also conducted by our study in the lateral neck (19). We hypothesized that the location of LNs would affect the cutoff value and derived it by an ROC curve analysis; the best threshold value was 14.6 ng/mL, indicating that the concentration of Tg in the surrounding tissues of the thyroid may be higher.



**Figure 4**  
Receiver operator characteristics for FNA-Tg.

**Table 2** Comparison of test accuracies of different diagnostic methods.

	Sensitivity	Specificity	PPV	NPV	Accuracy	P <sup>a</sup>
FNA-C	85.1 (63/74)	91.4 (53/58)	92.6 (63/68)	82.8 (53/64)	87.9 (116/132)	
FNA-Tg						
FNA-Tg > 14.6 ng/mL	85.1 (63/74)	84.5 (49/58)	87.5 (63/72)	81.7 (49/60)	84.8 (112/132)	0.454
FNA-Tg > 1 ng/mL	91.9 (68/74)	72.4 (42/58)	81.0 (68/84)	87.5 (42/48)	83.3 (110/132)	0.238
FNA-C + Tg						
FNA-Tg > 14.6 ng/mL	93.2 (69/74)	84.5 (49/58)	88.5 (69/78)	90.7 (49/54)	89.4 (118/132)	0.754
FNA-Tg > 1 ng/mL	93.2 (69/74)	72.4 (42/58)	81.2 (69/85)	89.4 (42/47)	84.1 (111/132)	0.332

<sup>a</sup>The accuracy of FNA-Tg vs FNA-C and FNA-C + Tg vs FNA-C were compared using McNemar test.

The rise of cutoff value increased false negative in five cases having FNA-Tg over 1 ng/mL but less than 14.6 ng/mL. The results of FNA-C were malignant or suspicious malignant, and metastases were confirmed by postoperative pathology. Washout Tg detection might be helpful when the aspirated cells are insufficient in FNA-C. Among the 16 cases with false-negative FNA-C results, five were revealed to be metastasis by elevated FNA-Tg levels; all were higher than 14.6 ng/mL. Taking 1 ng/mL as the threshold value did not improve the sensitivity but reduced the specificity and the accuracy. Since the diagnostic accuracy was not improved for both threshold values compared with FNA-C alone, we recommend FNA-C as the gold standard for diagnosing PTC central compartment metastasis.

The operational difficulty of central neck FNA could also be one of the factors reducing the accuracy of washout Tg. The diameter of LNs in level VI is small, interfered by the trachea and sternum, making it more difficult to discover and localized by ultrasound (12). The missed abnormal LNs will increase the false-negative rate. Alternatively, LNs located on the dorsal side of the thyroid gland are almost impossible to reach without passing through the gland due to the obstruction of the trachea and common carotid artery, which may increase the false-positive rate.

HT is another factor that influences preoperative diagnosis. PTC with concomitant HT is very common (24), in which reactive hyperplasia in central LNs is often observed. The hyperplastic LNs could mimic metastatic LNs and exhibit benign in FNA, thus missing the real malignant LNs. Most false-negative LNs (4/5) in this study were with HT, showing that HT may interfere with the determination of target LNs and affect the accuracy. Therefore, for PTC patients combined with HT, a negative FNA result in the central neck should exclude central area metastasis with caution.

The ultrasound features of central neck LNs differed from that of the lateral neck. Central LNs were smaller and rounded in shape. Sometimes, hyperplastic parathyroid glands, tracheal or esophageal diverticulum, unabsorbed hemostatic material, or residual thyroid after operation may be mistaken for LNs (25). The complexity of anatomical structure in the central neck may also have an impact on the diagnosis. In our study, a parathyroid gland and a residual thyroid tissue were misdiagnosed as metastatic LNs. It is difficult to puncture the parathyroid gland without passing through the thyroid, so a washout parathyroid hormone test may be helpful instead of a washout Tg test. Although some scholars believed that measuring FNA-Tg of space-occupying lesions in the

**Table 3** Clinicopathologic risk factors and their correlation with misdiagnosis.

Variables	No. of false-negative FNA-Tg (%)	P value	No. of false-positive FNA-Tg (%)	P-value
Lymph node size (cm)		0.337		0.472
<1	6/89 (7)		5/89 (6)	
≥1	5/43 (12)		4/43 (9)	
Ipsilateral thyroid status <sup>a</sup>		1.000		0.452
Intact or partial residue	9/100 (9)		6/100 (6)	
Absence	2/32 (6)		3/32 (9)	
Lymph node location	-	1.000		0.073
Pre- or paratracheal	11/125 (9)		7/125 (6)	
Parathyroid	0/7 (0)		2/7 (29)	
Hashimoto's thyroiditis		0.062		1.000
Yes	8/59 (14)		4/59 (7)	
No	3/73 (4)		5/73 (7)	

<sup>a</sup>Evaluated by ultrasound.

thyroid bed can help diagnose tumor recurrence (26), it had limited value in differentiating residual thyroid and metastatic LNs.

The level of serum Tg may also be a potential source of bias. FNA-Tg/serum-Tg ratio was used as a threshold value in some studies to eliminate the contamination of serum Tg during aspiration (27). Our study tested serum Tg but did not include it in the calculation. The main consideration was that serum Tg and FNA-Tg were not collected simultaneously; there could have been FNA-induced changes in serum-Tg during the gap, leading to deviations (28). A 30% increase in serum Tg level after FNA compared to baseline has been reported in a study (29). The effect of Tg antibody (TgAb) on diagnostic efficacy may also be ignored. The literature review has revealed that the sensitivity and specificity of FNA-Tg were excellent even in the presence of Tg-Ab (30, 31).

Our study has several limitations. First, this retrospective study only included PTC patients who underwent FNA with washout Tg tests of the central neck, some degree of selection bias may exist. Second, not all lesions were confirmed by histopathology, and occult metastasis may be missed in the cases of negative results by follow-up imaging. Third, the sample size of our study was relatively small, especially for cases after thyroidectomy.

## Conclusions

In conclusion, FNA is very useful in evaluating central neck metastasis in PTC patients. However, measurement of Tg levels in FNA washout cannot further improve the diagnostic accuracy; FNA-C remains the gold standard. Further study is needed to accurately detect metastatic LNs in the central neck to avoid insufficient or excessive treatment.

### Declaration of interest

The authors declare that there is no conflict of interest that could be perceived as prejudicing the impartiality of the research reported.

### Funding

This research did not receive any specific grant from any funding agency in the public, commercial or not-for-profit sector.

### Statement of ethics

All procedures performed in this study involving human participants complied with the ethical standards of the institutional and/or national research committee and with the 1964 Helsinki Declaration and its later

amendments or comparable ethical standards. This study was approved by the Institutional Review Board of the Peking University Cancer Hospital (No. 2020KT106). The requirement for informed consent was waived because patient records were anonymized and de-identified before analysis.

### Availability of data and materials

Some or all datasets generated during and analyzed during the current study are not publicly available but are available from the corresponding author on reasonable request.

### Author contribution statement

Song Y: designed the study, performed fine-needle aspiration and surgical procedures, performed the statistical analysis, interpreted the data and drafted the manuscript; Wang J: performed fine-needle aspiration and surgical procedures; Zhu Y: performed cytopathological diagnosis; Xu G: performed fine-needle aspiration and surgical procedures; Wang T: performed fine-needle aspiration and surgical procedures; Zhang B: designed the study, performed surgical procedures and revised the manuscript. All authors read and approved the final manuscript.

### Acknowledgements

We would like to thank Dr Zhongyi Zhang and colleagues for their contributions in ultrasonic screening and diagnosis.

## References

- Megwalu UC & Moon PK. Thyroid cancer incidence and mortality trends in the United States: 2000–2018. *Thyroid* 2022 **32** 560–570. (<https://doi.org/10.1089/thy.2021.0662>)
- Schuff KG. Management of recurrent/persistent papillary thyroid carcinoma: efficacy of the surgical option. *Journal of Clinical Endocrinology and Metabolism* 2011 **96** 2038–2039. (<https://doi.org/10.1210/jc.2011-1663>)
- Feng JW, Qin AC, Ye J, Pan H, Jiang Y & Qu Z. Predictive factors for lateral lymph node metastasis and skip metastasis in papillary thyroid carcinoma. *Endocrine Pathology* 2020 **31** 67–76. (<https://doi.org/10.1007/s12022-019-09599-w>)
- Kim DH, Kim GJ, Kim SW & Hwang SH. Predictive value of ipsilateral central lymph node metastasis for contralateral central lymph node metastasis in patients with thyroid cancer: systematic review and meta-analysis. *Head and Neck* 2021 **43** 3177–3184. (<https://doi.org/10.1002/hed.26787>)
- Haugen BR, Alexander EK, Bible KC, Doherty GM, Mandel SJ, Nikiforov YE, Pacini F, Randolph GW, Sawka AM, Schlumberger M, *et al.* 2015 American Thyroid Association management guidelines for adult patients with thyroid nodules and differentiated thyroid cancer: the American Thyroid Association guidelines task force on thyroid nodules and differentiated thyroid cancer. *Thyroid* 2016 **26** 1–133. (<https://doi.org/10.1089/thy.2015.0020>)
- Sanabria A, Betancourt-Agüero C, Sánchez-Delgado JG & García-Lozano C. Prophylactic central neck lymph node dissection in low-risk thyroid carcinoma patients does not decrease the incidence of locoregional recurrence: a meta-analysis of randomized trials. *Annals of Surgery* 2022 **276** 66–73. (<https://doi.org/10.1097/SLA.0000000000005388>)
- Kim BY, Choi N, Kim SW, Jeong HS, Chung MK & Son YI. Randomized trial of prophylactic ipsilateral central lymph node dissection in patients with clinically node negative papillary thyroid

- microcarcinoma. *European Archives of Oto-Rhino-Laryngology* 2020 **277** 569–576. (<https://doi.org/10.1007/s00405-019-05702-3>)
- 8 Ahn JH, Kwak JH, Yoon SG, Yi JW, Yu HW, Kwon H, Kim SJ & Lee KE. A prospective randomized controlled trial to assess the efficacy and safety of prophylactic central compartment lymph node dissection in papillary thyroid carcinoma. *Surgery* 2022 **171** 182–189. (<https://doi.org/10.1016/j.surg.2021.03.071>)
  - 9 Ito Y, Uruno T, Nakano K, Takamura Y, Miya A, Kobayashi K, Yokozawa T, Matsuzuka F, Kuma S, Kuma K, *et al.* An observation trial without surgical treatment in patients with papillary microcarcinoma of the thyroid. *Thyroid* 2003 **13** 381–387. (<https://doi.org/10.1089/105072503321669875>)
  - 10 Saravana-Bawan B, Bajwa A, Paterson J & McMullen T. Active surveillance of low-risk papillary thyroid cancer: a meta-analysis. *Surgery* 2020 **167** 46–55. (<https://doi.org/10.1016/j.surg.2019.03.040>)
  - 11 Ito Y, Miyauchi A & Oda H. Low-risk papillary microcarcinoma of the thyroid: a review of active surveillance trials. *European Journal of Surgical Oncology* 2018 **44** 307–315. (<https://doi.org/10.1016/j.ejso.2017.03.004>)
  - 12 Zhao H & Li H. Meta-analysis of ultrasound for cervical lymph nodes in papillary thyroid cancer: diagnosis of central and lateral compartment nodal metastases. *European Journal of Radiology* 2019 **112** 14–21. (<https://doi.org/10.1016/j.ejrad.2019.01.006>)
  - 13 Min Y, Huang Y, Wei M, Wei X, Chen H, Wang X, Chen J, Xiang K, Feng Y & Yin G. Preoperatively predicting the central lymph node metastasis for papillary thyroid cancer patients with Hashimoto's thyroiditis. *Frontiers in Endocrinology* 2021 **12** 713475. (<https://doi.org/10.3389/fendo.2021.713475>)
  - 14 Zhu XH, Zhou JN, Qian YY, Yang K, Wen QL, Zhang QH, Xia L, Ge MH & Sun CX. Diagnostic values of thyroglobulin in lymph node fine-needle aspiration washout: a systematic review and meta-analysis diagnostic values of FNA-Tg. *Endocrine Journal* 2020 **67** 113–123. (<https://doi.org/10.1507/endocrj.EJ18-0558>)
  - 15 Pak K, Suh S, Hong H, Cheon GJ, Hahn SK, Kang KW, Kim EE, Lee DS & Chung JK. Diagnostic values of thyroglobulin measurement in fine-needle aspiration of lymph nodes in patients with thyroid cancer. *Endocrine* 2015 **49** 70–77. (<https://doi.org/10.1007/s12020-014-0410-z>)
  - 16 Grani G & Fumarola A. Thyroglobulin in lymph node fine-needle aspiration washout: a systematic review and meta-analysis of diagnostic accuracy. *Journal of Clinical Endocrinology and Metabolism* 2014 **99** 1970–1982. (<https://doi.org/10.1210/jc.2014-1098>)
  - 17 American Thyroid Association Surgery Working Group, American Association of Endocrine Surgeons, American Academy of Otolaryngology-Head and Neck Surgery, American Head and Neck Society, Carty SE, Cooper DS, Doherty GM, Duh QY, Kloos RT, Mandel SJ, *et al.* Consensus statement on the terminology and classification of central neck dissection for thyroid cancer. *Thyroid* 2009 **19** 1153–1158. (<https://doi.org/10.1089/thy.2009.0159>)
  - 18 Song Y, Xu G, Wang T, Zhu Y, Zhang Y & Zhang B. Surgeon-performed fine-needle aspiration for lymph nodes behind the big cervical vessels in papillary thyroid cancer. *Laryngoscope Investigative Otolaryngology* 2022 **7** 646–651. (<https://doi.org/10.1002/lio2.766>)
  - 19 Song Y, Xu G, Wang T & Zhang B. Lateral neck multilevel fine-needle aspiration cytology and thyroglobulin estimation in papillary thyroid carcinoma. *Laryngoscope Investigative Otolaryngology* 2021 **6** 570–575. (<https://doi.org/10.1002/lio2.570>)
  - 20 Pacini F, Fugazzola L, Lippi F, Ceccarelli C, Centoni R, Miccoli P, Elisei R & Pinchera A. Detection of thyroglobulin in fine needle aspirates of nonthyroidal neck masses: a clue to the diagnosis of metastatic differentiated thyroid cancer. *Journal of Clinical Endocrinology and Metabolism* 1992 **74** 1401–1404. (<https://doi.org/10.1210/jcem.74.6.1592886>)
  - 21 Frasoldati A, Toschi E, Zini M, Flora M, Caroggio A, Dotti C & Valcavi R. Role of thyroglobulin measurement in fine-needle aspiration biopsies of cervical lymph nodes in patients with differentiated thyroid cancer. *Thyroid* 1999 **9** 105–111. (<https://doi.org/10.1089/thy.1999.9.105>)
  - 22 Kim MJ, Kim EK, Kim BM, Kwak JY, Lee EJ, Park CS, Cheong WY & Nam KH. Thyroglobulin measurement in fine-needle aspirate washouts: the criteria for neck node dissection for patients with thyroid cancer. *Clinical Endocrinology* 2009 **70** 145–151. (<https://doi.org/10.1111/j.1365-2265.2008.03297.x>)
  - 23 Moon JH, Kim YI, Lim JA, Choi HS, Cho SW, Kim KW, Park HJ, Paeng JC, Park YJ, Yi KH, *et al.* Thyroglobulin in washout fluid from lymph node fine-needle aspiration biopsy in papillary thyroid cancer: large-scale validation of the cutoff value to determine malignancy and evaluation of discrepant results. *Journal of Clinical Endocrinology and Metabolism* 2013 **98** 1061–1068. (<https://doi.org/10.1210/jc.2012-3291>)
  - 24 Vita R, Ieni A, Tuccari G & Benvenega S. The increasing prevalence of chronic lymphocytic thyroiditis in papillary microcarcinoma. *Reviews in Endocrine and Metabolic Disorders* 2018 **19** 301–309. (<https://doi.org/10.1007/s11154-018-9474-z>)
  - 25 Shin JH, Han BK, Ko EY & Kang SS. Sonographic findings in the surgical bed after thyroidectomy: comparison of recurrent tumors and nonrecurrent lesions. *Journal of Ultrasound in Medicine* 2007 **26** 1359–1366. (<https://doi.org/10.7863/jum.2007.26.10.1359>)
  - 26 Suh YJ, Son EJ, Moon HJ, Kim EK, Han KH & Kwak JY. Utility of thyroglobulin measurements in fine-needle aspirates of space occupying lesions in the thyroid bed after thyroid cancer operations. *Thyroid* 2013 **23** 280–288. (<https://doi.org/10.1089/thy.2011.0303>)
  - 27 Chung J, Kim EK, Lim H, Son EJ, Yoon JH, Youk JH, Kim JA, Moon HJ & Kwak JY. Optimal indication of thyroglobulin measurement in fine-needle aspiration for detecting lateral metastatic lymph nodes in patients with papillary thyroid carcinoma. *Head and Neck* 2014 **36** 795–801. (<https://doi.org/10.1002/hed.23371>)
  - 28 Zhao H, Wang Y, Wang MJ, Zhang ZH, Wang HR, Zhang B & Guo HQ. Influence of presence/absence of thyroid gland on the cutoff value for thyroglobulin in lymph-node aspiration to detect metastatic papillary thyroid carcinoma. *BMC Cancer* 2017 **17** 296. (<https://doi.org/10.1186/s12885-017-3296-3>)
  - 29 Hong CM, Jeong JH, Son SH, Lee CH, Jeong SY, Lee SW, Lee J & Ahn BC. Serum thyroglobulin elevation after needle aspiration of the lymph nodes: the predictive value for detecting metastasis in papillary thyroid cancer patients – a pilot study. *Medicine* 2019 **98** e16461. (<https://doi.org/10.1097/MD.00000000000016461>)
  - 30 Jiang HJ & Hsiao PJ. Clinical application of the ultrasound-guided fine needle aspiration for thyroglobulin measurement to diagnose lymph node metastasis from differentiated thyroid carcinoma-literature review. *Kaohsiung Journal of Medical Sciences* 2020 **36** 236–243. (<https://doi.org/10.1002/kjm2.12173>)
  - 31 Konca Degertekin C, Yalcin MM, Cerit T, Ozkan C, Kalan I, Iyidir OT, Altinova AE, Akturk M, Toruner F, Akin M, *et al.* Lymph node fine-needle aspiration washout thyroglobulin in papillary thyroid cancer: diagnostic value and the effect of thyroglobulin antibodies. *Endocrine Research* 2016 **41** 281–289. (<https://doi.org/10.3109/07435800.2016.1141936>)

Received in final form 12 August 2022

Accepted 29 September 2022

Accepted Manuscript published online 29 September 2022