

REVIEW

Questions concerning fertility preservation during transition in girls with Turner syndrome: review of the literature

Małgorzata Więcek¹, Jakub Gawlik², Zuzanna Nowak² and Aneta Gawlik¹

¹Department of Pediatrics and Pediatric Endocrinology, Faculty of Medical Sciences, Medical University of Silesia, Katowice, Poland

²Student Scientific Society at the Department of Pathophysiology, Jagiellonian University Medical College, Krakow, Poland

Correspondence should be addressed to A Gawlik: agawlik@sum.edu.pl

Abstract

Loss of fertility is one of the most important concerns facing Turner syndrome (TS) patients as they transition into adult health care. Due to the limited and rapidly decreasing ovarian reserve, many TS patients require fertility preservation (FP) techniques to preserve their reproductive potential until they are ready to pursue procreation. One has to also remember about the additional risks connected with pregnancy in TS patients. In order to determine the optimal time for introducing FP techniques and decrease the chance of an unnecessary intervention, markers and procedures assessing ovarian reserve have been developed. The exposure to potential cardiovascular complications should be determined before FP to avoid unnecessary procedures in patients with potential contraindications to pregnancy. The aim of the present review is to answer the following three questions important for successful preservation of fertility and safe pregnancy in TS: which markers of ovarian reserve should be used as selection criteria for FP? Which methods of FP are the safest and most effective? Are there any cardiovascular contraindications to FP? For each of those questions, separate literature searches have been conducted. A total of 86 articles have been included in this review: 34 for the first question, 35 for the second, and 17 for the third. Ovarian reserve markers and cardiovascular contraindications to pregnancy should be established before FP; however, there are no unambiguous indicators as to which patients should be disqualified from the FP and more evidence is needed in this subject.

Key Words

- ▶ Turner syndrome
- ▶ fertility preservation
- ▶ ovarian reserve
- ▶ cardiovascular risk

Endocrine Connections
(2022) 11, e220344

Introduction

Turner syndrome (TS) is the most common sex chromosomal abnormality found in females, with the prevalence of about 1 in 2000 to 1 in 2500 live female births (1). It is a result of a partial or complete loss of one of the X chromosomes, and depending on the level of mosaicism (the proportion of affected cells to healthy ones), it can vary in severity (2). Short stature and primary ovarian failure (OF) are the hallmarks of TS, while it can also manifest with cardiac and renal anomalies, autoimmune disorders, and hearing loss (2). Infertility is reported as one of the most important concerns facing TS patients (3), as only about 5% will

ever experience spontaneous pregnancy (4, 5). Alongside puberty induction and cardiovascular status, fertility preservation (FP) is one of the most important issues during the transition process in TS. With the advent of assisted reproductive technologies (ARTs), medicine brought new hope for these patients. However, due to the limited and rapidly decreasing ovarian reserve, many of them would not be able to benefit from ART upon reaching adulthood. FP techniques, such as cryopreservation of oocytes or ovarian tissue, introduced at a young age are thus essential in giving these patients a chance at reproduction and parenthood.

As FP techniques are invasive and may cause complications, they should be introduced only when tangible benefit is possible. That is why a number of markers and procedures have been developed to properly assess the ovarian reserve, before attempting FP (6, 7). ART should also be applied with caution, as pregnancy may carry serious risks for TS women. Therefore, the exposure for potential cardiovascular complications should also be determined before the FP to avoid unnecessary procedures in patients with contraindications to pregnancy (2).

The aim of this paper is to sum up the recent literature concerning FP in TS and to establish which factors should be taken into consideration during preparation for the FP procedures.

Material and methods

In our study, we set out to answer three questions important for successful preservation of fertility and safe pregnancy in TS. For each of those questions, separate literature searches have been conducted. Articles have been acquired from PubMed and Embase databases, based on keyword searches (described in detail for each question below), as well as selection criteria, which included: publication date between January 2002 and July 2022, written in English, published in a scholarly peer-reviewed journal. Additional sources were collected from reference lists found in aforementioned articles.

Which markers of ovarian reserve should be used as selection criteria for FP?

Keywords for this question included: ‘Turner Syndrome’, ‘Fertility Preservation’, ‘Ovarian Reserve’, ‘Mosaicism’, ‘FSH’, ‘Anti-Mullerian Hormone’, and ‘Inhibins’.

Which methods of FP are the safest and most effective?

Keywords included: ‘Turner Syndrome’, ‘Fertility Preservation’, ‘Oocyte Cryopreservation’, ‘Ovarian Tissue Cryopreservation’, and ‘Embryo Cryopreservation’.

Are there any cardiovascular contraindications to FP?

Keywords included: ‘Turner Syndrome’ and ‘Pregnancy Outcome’.

Results

Eighty-six articles were included in this review. Detailed selection process for each question has been presented on flow charts (Figs 1, 2 and 3).

Which markers of ovarian reserve should be used as selection criteria for FP?

Thirty-four articles were used in the preparation of this section (Fig. 1).

Which methods of FP are the safest and most effective?

Thirty-five studies were included in this section (Fig. 2).

Are there any cardiovascular contraindications to FP?

Due to finding a sufficient number of original research papers, case reports were excluded from this literature search. Seventeen articles concerning pregnancy outcomes in women with TS were included in this section (Fig. 3). Numbers of TS patients, pregnancies, dilation of aorta

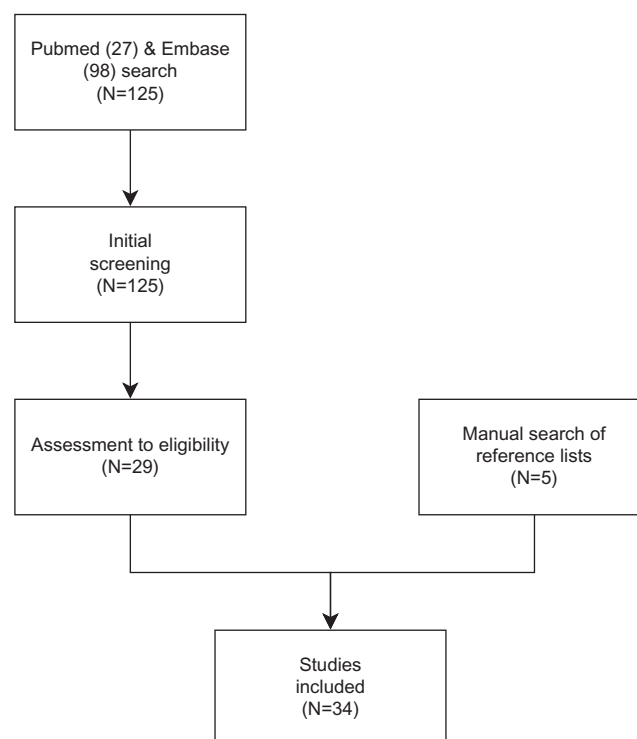


Figure 1
Flow chart for question 1.

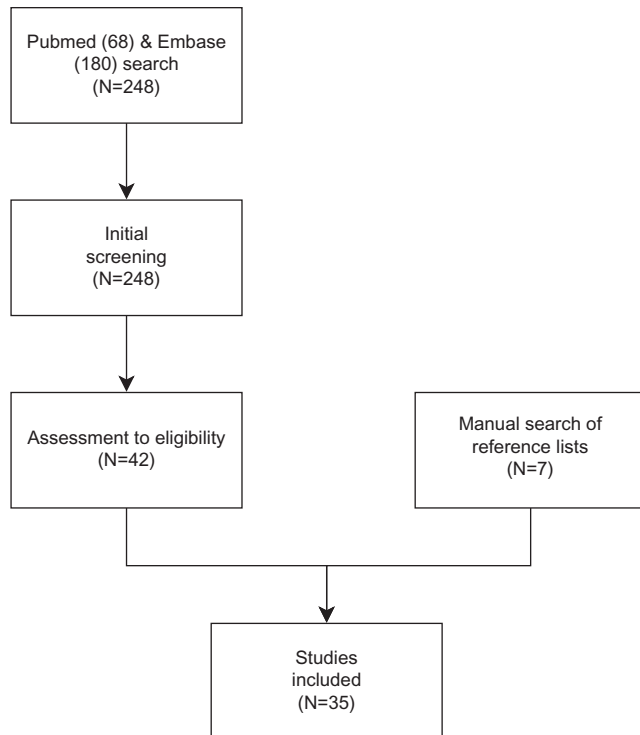


Figure 2
Flow chart for question 2.

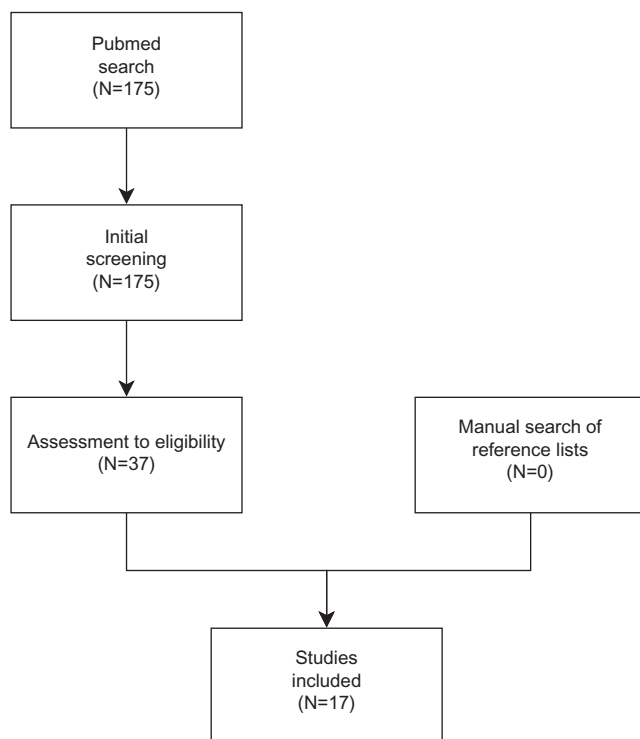


Figure 3
Flow chart for question 3.

(AoD), and the rate of cardiac screening before pregnancy were systematized and presented in **Table 1**. **Table 2** shows the characteristics of women diagnosed with AoD.

Discussion

Which markers of ovarian reserve should be used as selection criteria for FP?

Accelerated follicular depletion and gonadal dysgenesis are the primary characteristics of TS (5). Although the initial migration of primordial germline cells does not seem to be impaired, patients with TS experience a steep loss of germ cells, with oocyte reserves depleted even in early childhood (7). FP procedures are invasive and come with a certain risk of complications (2); therefore, we should strive for efficient and accurate methods to properly assess the reserve before they are implemented. Below, we analyse the currently available markers and procedures.

Karyotype

Patients diagnosed with mosaicism often present with milder TS stigmata and fewer characteristic pathologies. Generally, mosaic patients (either with 45,X/46,XX or 45,X/47,XXX) more frequently present with spontaneous and cyclical menstruation (8). It is believed that the quantity of oocytes and ovarian function is determined by the degree of mosaicism (proportion of 46,XX cells) in the ovaries (9), with women who have a higher proportion of the 46,XX line achieving more viable oocytes (10) and experiencing OF later in life (11). In a study examining 328 TS patients of various karyotypes, Noordman *et al.* determined that gonadal dysfunction was the most favourable in 45,X/46,XX mosaic karyotypes in terms of spontaneous puberty (12). Additionally, 70% of the spontaneous pregnancies, seen in 2–5% of the TS population, are observed in 45,X/46,XX mosaic patients (4). Finally in a study by Borgström *et al.*, 45,X/46,XX mosaicism has been determined as the best predictive factor for finding remaining follicles in the ovaries of girls with TS in terms of sensitivity (13). It is, however, worth to mention that even in non-mosaic TS, girls primordial and primary follicles have been observed up to the age of 13 (10) and viable oocytes collection has been documented (14). This phenomenon could be explained by the ‘cryptic mosaicism’ theory (15, 16), which states that all surviving TS embryos diagnosed as non-mosaic 45,X are actually mosaics for a ‘rescue line’ that includes a viable karyotype. Reports show that even in cases when 45,X karyotype is confirmed in lymphocytes, buccal cells, and urine cells,

Table 1 Summary of the literature analysed for question 3.

Reference number	Journal	Year of publication	Type of study	Cases	Pregnancies	Number of dissections	Prepregnancy cardiac screening
Calanchini et al. (80)	<i>Fertility and Sterility</i>	2020	Retrospective	156	32 (18 spontaneous, 7 OD with live birth, 7 OD with miscarriage)	4/131 nulliparous 0/25 pregnant with live births	12/25
Grevall et al. (77)	<i>Heart</i>	2021	Retrospective	60	68 pregnancies in 60 women	0/68 nulliparous; 0/60 6 months postpartum	128/128
Kooijman et al. (81)	<i>American Journal of Cardiology</i>	2021	Retrospective	30	30	0/30	22/30
Cadoret et al. (82)	<i>European Journal of Obstetrics and Gynecology and Reproductive Biology</i>	2018	Retrospective	103	170: 35 spontaneous, 5 by means of intra-conjugal ART, 130 with OD	0/103	49/62 (79%) after 2009 vs 56/93 (60%) before 2009
Cauldwell et al. (78)	<i>International Journal of Obstetrics and Gynaecology</i>	2021	Retrospective	84	127	2/84 (2.38%)	73/127 (57.4%)
Obata et al. (83)	<i>Clinical Pediatric Endocrinology</i>	2020	Retrospective	20	20 (18 with live birth)	0/20	MRI of the aorta: 5/20 (25%) ECG: 13/20 (65.0%)
Hadnott et al. (84)	<i>Fertility and Sterility</i>	2011	Retrospective	10	10 (5 spontaneous pregnancies, 5 OD)	0/10	0/10
Bryman et al. (5)	<i>Fertility and Sterility</i>	2011	Retrospective	57	124	1/57 (1.75%)	No data
Donadille et al. (4)	<i>Fertility and Sterility</i>	2015	Retrospective	480	52 in 27 women (spontaneous)	0/52	25/30 pregnancies
Mercadal (85)	<i>Human Reproduction</i>	2011	Retrospective	23	18 (OD)	0/23	All
Doğer et al. (86)	<i>Reproductive Biology and Endocrinology</i>	2015	Retrospective	22	23	No data	No data
Chevalier et al. (79)	<i>Journal of Clinical Endocrinology and Metabolism</i>	2011	Retrospective	93	93	2/93 (2.2%)	56/93 (60.2%); echo: 31/93 (33.3%); thoracic MRI: 4/93 (4.3%); aortic diameter: 6/93 (6.4%)
Deligeoroglou et al. (87)	<i>Journal of Obstetrics and Gynaecology</i>	2016	Retrospective	4	4	0/4	All
Hagman et al. (88)	<i>Human Reproduction</i>	2013	Retrospective	110	122	1/110 (0.9%)	73/115 (63.5)
Hagman et al. (89)	<i>Journal of Clinical Endocrinology and Metabolism</i>	2011	Retrospective	115	205	1/115 (0.87%)	No data
Bodri et al. (90)	<i>Human Reproduction</i>	2005	Retrospective	21	12	0/12	All
Giles et al. (91)	<i>Fertility and Sterility</i>	2020	Retrospective	166	93	0/93	All

OD, oocyte donation.

cryptic mosaicism can still be present in ovarian tissue (17). Taking that into consideration, we propose that non-mosaic karyotype should be treated as a factor negatively affecting chances for finding viable oocytes but not an absolute contraindication for FP.

Age

Studies show that the initial migration of germline cells to the genital ridges is undisturbed in TS fetuses (18), and germ cells can be found in ovaries <25th gestational week (GW) (19). Their steep loss is, however, observed

as they enter the early stage of meiotic prophase (20), around the second and third trimesters. Comparing to age-matched controls at 20 GW, the proportion of apoptotic oocytes is markedly higher in TS, reaching even 70% in TS and only 7% in controls (21). This results in a drastically decreased number of germ cells even in the prenatal stage. Additionally, the formation of primordial follicles is often impaired and instead replaced by connective tissue proliferation (19). Total depletion of the oocyte reserve can be already observed in the first years of life in some non-mosaic patients. A recent study asserting the connection between OF and karyotype showed that the median age of OF was 10 years in 45,X patients, with 100% of this karyotype succumbing to OF. In contrast, only 1 out of 13 studied patients with 45,X/46,XX mosaicism (mean 10 years of age) suffered from OF, which was however diagnosed at the age of 4. This study has also established a negative correlation between the proportion of 45,X cells in the peripheral karyotype and age of OF (11).

Assuming a mean age of diagnosis of TS at about 5-7 years of age, this leaves a very limited amount of time to consider FP. In order to ensure the best outcomes, this topic should be discussed as soon as possible after the diagnosis, even in infancy. In mosaic patients, this window of opportunity may be wider, although one cannot forget about possible discrepancies between peripheral and oocyte karyotype determination, which could be responsible for earlier OF in these patients.

FSH

Follicle-stimulating hormone (FSH) has been shown to display a biphasic pattern of secretion in TS population independent of studied karyotype (22, 23, 24, 25). It remains elevated from birth to around the age of 5, when it drops to pre-pubertal levels, and increases again at the age of 10, reaching postmenopausal levels a few years later. While the same pattern is observed in healthy girls, there are some clear differences. Most studies agree that in TS patients who suffered from the most severe OF, FSH levels are markedly increased during infancy and at the time of expected puberty (23). Ages 5–10, however, are a point of contention, with earlier publications stating that FSH levels recorded during this time are not elevated compared to pre-pubertal healthy girls (23, 24), while some recent studies using ultrasensitive assays claim that the FSH decline after the age of 5 does not in fact reach normal levels and could be used to diagnose girls with unexplained short stature (22). Nevertheless, diagnosis of OF based on FSH levels can be made only before the age of 5 and in adolescence.

Taking into account that with the advent of ovarian tissue cryopreservation (OTC), midchildhood could become a vital time for FP; this poses as a considerable obstacle for using FSH as a viable marker.

Scarce information on the relation between the presence of available oocytes and FSH in TS is available, with most studies describing the adolescent and adult TS populations. In a study by Borgstrom *et al.*, FSH within normal levels for age and stage of puberty predicted the presence of follicles obtained during laparoscopic biopsy with accuracy of 73%, FSH<11 mIU/mL was characterized with 69% sensitivity (second highest sensitivity after mosaic karyotype), and FSH>15 mIU/mL displayed 77% specificity (13). Based on the analysis of cases of oocyte cryopreservation (OC) by Schleedoorn, we can however see that in 8 out of 18 recorded instances of successful oocyte retrieval, FSH before ovarian stimulation was above >15 mIU/mL. Better results are achieved when FSH is combined with other factors, as is shown in a retrospective study by Volodarsky-Perel (26). Combining FSH ≤ 20 mIU/mL with anti-Mullerian hormone (AMH) > 0.16 ng/mL and ultrasonographic finding of ≥1 antral follicle yielded a 100% success rate of finding follicles in OTC, if ≥2 parameters were positive.

Even though presently we lack sufficient results that would link FSH concentrations with follicle count, a number of longitudinal studies are on the horizon that could shed light on this topic (27, 28).

AMH

AMH is secreted by the granulosa cells of preantral follicles in the process of determining the dominant follicle. It has been closely studied in general population with regard to predicting follicular reserve and follicle recruitment (29) and correlates well with antral follicle count in adults (30) and adolescents (31). In younger paediatric patients, reports on this correlation are however inconclusive, with some studies reporting positive correlation (32) and some none (33, 34). In TS, AMH concentrations are higher in patients with spontaneous puberty and mosaic karyotype (35, 36). In a study of TS patients by Borgstrom *et al.*, AMH concentrations above 2 pmol/L (0.28 ng/mL) (accepted norm for teenagers) predicted the presence of follicles in laparoscopic biopsy, with an accuracy of 81%, a sensitivity of 64%, and a specificity of 88% (20). Other studies also used this cut-off point as an indication for oocyte (14) or OTC (26) with good results. However, the low sensitivity makes this marker prone to omission of viable patients; that is why repeated measurements alongside other markers are recommended.

Table 2 Characteristics of pregnant women with TS diagnosed with AoD.

Author	Case number	Age of AoD	Karyotype	Heart defect	ASI/aortic root diameter	Maternal outcomes	Fetal outcomes	Pregnancy	Pregnancy week when AoD
Cauldwell <i>et al.</i> (78)	1	No data	45,X	BAV	15	Survived	Stillborn	OD	18 week
Cauldwell <i>et al.</i> (78)	2	No data	45,X	BAV	16	Died	No data	OD	37 week
Bryman <i>et al.</i> (5)	3	38	Y-chromosome frag- ment	CoA	No data	Survived	No data	Second SP	7 month
Chevalier <i>et al.</i> (79)	4	33	No data	BAV, aortic dilatation	39 mm	Died	No data	OD	38 week
Chevalier <i>et al.</i> (79)	5	33	No data	grade 1 aortic insufficiency; aortic dilatation	35 mm	Died	No data	OD	7 days after cesarian section
Hagman <i>et al.</i> (88)	6	28	Mosaicism	Healthy	No data	Survived	No data	OD	20 days after delivery
Hagman <i>et al.</i> (89)	7	36	45,X in 46 cells and a Y mosaicism in four cells	No data	No data	Survived	Survived	Second SP	32

AoD, dilatation of the aorta; BAV, bicuspid aortic valve; CoA, coarctation of the aorta.

In recent years, AMH has emerged as the dominant marker determining the feasibility of FP. In recommendations by Oktay *et al.*, decrease of AMH <2 ng/mL (14.28 pmol/L) in pre-pubertal girls is an indication for OTC (6), while in recommendations by Nawroth *et al.*, AMH plays an even more prominent role, with AMH <0.5 ng/mL (3.57 pmol/L) being a contraindication for cryopreservation in non-mosaic patients (37).

Inhibin B

Inhibin B is produced by small developing follicles and thus has been proposed as a marker of ovarian reserve. Its concentration decreases earlier than any other marker of ovarian reserve and is more specific to decline in follicle number than inhibin A (38). Detectable levels of inhibin B are present in pre-pubertal girls (at a detection limit of 20 pg/mL), in contrast to most adolescent TS patients without ovarian function (39). In a longitudinal study by Hagen *et al.*, undetectable inhibin B in all measurements throughout childhood predicted premature OF in 20/20 patients, and at least one detectable measurement has been recorded in 9/10 with spontaneous puberty (23). This shows that repeatable inhibin B measurements could be useful in predicting the condition of ovarian reserve; however isolated undetectable concentrations are not an absolute contraindication for FP. No studies are currently available directly correlating inhibin B concentrations with follicle count.

Atrial follicle count

Atrial follicle count (AFC) is an imaging technique which can be performed using transabdominal or transvaginal ultrasonography and MRI. The technique for performing AFC should be determined based on the patients' age and feasibility of examination, as effectiveness seems to be comparable. AFC has shown a strong positive correlation with AMH among healthy adolescent girls (31, 40), with some studies suggesting its interchangeability. However, when considering FP, especially in younger patients with non-mosaic karyotypes, AFC could provide invaluable first-hand information on the state of the ovarian reserve.

Which methods of FP are safest and most effective?

As previously mentioned, in most women with TS, a decline in ovarian function before reaching reproductive age is observed. Taking into account the limited and

ever-diminishing ovarian reserve in TS, breaching the topic of FP, evaluating ovarian reserve markers and proposing adequate FP procedures should be of utmost importance.

The main issue limiting the implementation of FP techniques is markedly reduced follicle pool, which can be depleted as soon as in pre-pubertal age (41, 42). As a consequence, it is advised to assess ovarian reserve at the time of diagnosis and, if necessary, quickly introduce FP techniques due to accelerated ovarian aging and considerable risk of primary OF (43). Non-mosaic karyotype is considered as a factor negatively affecting chances for finding viable oocytes in TS patients but not an absolute contraindication for FP. Accordingly, in this group, it is advised to preserve ovarian tissue as early as possible, even in infancy (7). Mosaic patients are believed to have spontaneous and cyclical menstruation (8) and more viable oocytes (10) and experience OF later in life (11). Therefore, 45,X/46,XX mosaic patients are in most cases advised to postpone FP procedures until menarche with a greater chance of succeeding (6, 7).

It is worth to remember that any implementation of FP techniques requires evaluation of the patients' emotional and physical readiness (44). Additionally, contradictions and risks connected with pregnancy should be discussed, so that an informed decision could be made by the patient or their parent (45).

Currently, only two well-established FP techniques for TS patients with preserved ovarian function are available: OC and embryo cryopreservation (EC). Another experimental technique is being introduced into clinical practice – OTC, applicable in pre-pubertal girls.

Women with exhausted ovarian reserve can be offered other options, which include *in vitro* fertilization with donor oocytes (IVF-DO), gestational surrogacy, and adoption.

Below, we will focus on techniques which allow for conception of biological offspring, as adoption, oocyte donation, or surrogacy are regulated by each country's individual law, analysis of which goes beyond the scope of this paper.

Oocyte cryopreservation

OC is considered to be a safe and effective technique of FP in women with mosaic TS (46, 47). It is dedicated for post-menarchal girls with normal ovarian function, as it requires gonadotropin stimulation (7). Additionally, its feasibility before menarche is limited because of physical, sexual, or psychosocial immaturity (48). Recently however, a case report by Azem *et al.* has been published describing a

successful retrieval and cryobanking of oocytes in a 7-year-old pre-pubertal TS patient (49). This could provide an alternative for OTC in younger TS patients.

Following the stimulation, ovarian response is monitored with the use of transabdominal ultrasound and serum o oestradiol levels (48). Finally, oocyte retrieval is performed transvaginally under general anaesthesia. Transabdominal retrieval is feasible but not recommended (50). *In vitro* maturation (IVM) is used to increase the yield of mature oocytes. Oocytes are then vitrified, which increases the post-thaw survival (even to 90–95%), comparing to slow freezing (9, 51). Vitrified oocytes show similar fertilization and pregnancy rates compared to fresh oocytes (51). Due to small yields in TS women, additional stimulation cycles are often required for a minimal number of 10 mature oocytes (50). DuoStim, which consists of two cycles of stimulation and oocyte retrieval, could also be used to maximize the yields in TS patients. In a case reported by Ito *et al.* using DuoStim, 10 and 9 oocytes were retrieved after two stimulation phases during one cycle, approximately doubling the yield (52).

The method also allows for pre-implantation genetic screening, which is important in TS patients, in order to screen out aneuploidic embryos (53).

In patients with preserved menstrual cycles, natural-cycle IVF is available. It is believed that oocytes retrieved from natural cycles might be of better quality and result in a healthier embryo (9). However, it prolongs the process of oocyte retrieval, which may be contraindicated in women with quickly diminishing ovarian function.

In a study by Oktay *et al.*, oocyte stimulation has been performed in three girls with mosaic TS. After an average of 11 days for ovarian stimulation between 7 and 19 oocytes were retrieved, of which 53% were mature. IVM yielded one additional oocyte in one case and five in another. In one case, the procedure had to be repeated due to small number of vitrified mature oocytes. No complications were described.

In another study by Talaulikar *et al.*, OC has been performed in seven women with TS (only one non-mosaic patient). Oocyte retrieval was successful in all women, with a mean of nine oocytes preserved, which was comparable to data from healthy women (46). As in the previous study, no complications were reported.

While the first pregnancy from OC was recorded as far back as in 1986 (54), only very recently we have seen the first TS pregnancy (55). Cryopreservation of 29 oocytes was performed in a mosaic (45,X/46,XX) 25-year-old patient. Post-thaw 23 oocytes survived (79.3%) and 13 were fertilized, resulting in three good quality blastocysts,

two of which were euploid. One was transferred to the uterus, resulting in a healthy live birth. It is however worth to mention that 5 years before IVF, the patient conceived spontaneously and gave birth to a healthy child.

Embryo cryopreservation

Although effective and well established in the general population, this method is less frequently performed in TS patients, who usually necessitate FP techniques at a young age, as it requires a sperm donor or a partner. It follows the steps described in OC up to the point of oocyte retrieval (7). The success rate of EC appears to be greater than in OC; however, this difference is negligible in younger patients (56).

In TS, pre-implantation genetic screening of the embryo is advised (57). Additionally, only one embryo should be implanted due to risks connected with pregnancy in TS (58).

Unfortunately, no reports of EC or pregnancies as a result of EC in TS patients have been found.

Ovarian tissue cryopreservation

OTC is a new and emerging method, which allows for FP in pre-pubertal girls who cannot wait for OC or EC. This makes it an appealing choice for TS patients, especially those with non-mosaic karyotype or with markedly reduced oocyte reserve in young age. Additionally, it is the only method which allows for preservation of both fertility and endocrine function (9). A panel of international experts in 2020 agreed that OTC should be offered to TS patients but only in a safe and controlled research setting (59).

The procedure involves laparoscopic removal of a part or a whole ovary, cryopreservation of the ovarian cortex, and subsequent auto-transplantation when the patient wants to pursue procreation. Transplantation can be orthotopic, which can even lead to a spontaneous pregnancy, or heterotopic, to s.c. tissue of the abdominal wall, forearm, and chest wall (60). Recent introduction of robot-assisted surgery and use of extracellular matrix scaffolds (AlloDerm) might lead to improvements in outcomes (61).

The effectiveness of OTC in TS patients might however be diminished due to the decreased ovarian reserve even in younger ages. To ensure the best outcomes, a whole ovary should be removed, so as to preserve as much follicles as possible (7, 9). Additionally, as the cryopreservation of the ovarian cortex only preserves the primordial and primary follicles, integrated oocyte aspiration from antral follicles

followed by IVM and OC should be used as a supplementary FP technique (43, 62, 63). Finally, to mitigate the oocyte loss connected with hypoxia during transplantation, vasculogenic factors, like sphingosine-1-phosphate (S1P), vascular endothelial growth factor (VEGF), or stromal cell enriched in CD34, could prove useful, although their clinical applicability is still being tested (50, 64, 65).

One has to remember about the disadvantages of OTC. As it involves two surgical interventions, it is characterized with greater risk for the patient than both OC and EC (47). Furthermore, the removal of the ovary for cryopreservation could also decrease chances of spontaneous puberty or accelerate OF (40). Nevertheless, for many patients with TS, it could be the only viable option of FP.

The first case of OTC in TS patients has been described in 2008 by Huang *et al.* (66), and in 2019 Mamsen *et al.* reported the outcomes of OTC in 15 girls with TS, ages 5–22.4 years. Oocytes were found in nine girls, of whom only one was non-mosaic at 5 years of age. Most ovaries (6/9) showed a high rate of abnormal follicle morphology. In one mosaic patient, IVM has been performed with 19% success rate, which, while lower than in general population, illustrates that TS oocytes from removed ovarian tissue can reach reproductive potential (67).

Although no pregnancies after OTC in TS patients have been reported, the ever-increasing number of live births from OTC in general population corroborates its effectiveness (68). In 2015, Demestre *et al.* described a case of pregnancy in a 27-year-old woman, after transplanting cryopreserved ovarian tissue, which was removed at the age of 13, before menarche (55). It was the first reported pregnancy from OTC performed before puberty, which is promising for TS patients from whom ovarian tissue has been harvested at a young age.

A deeper dive into the effectiveness of OCT in TS can be expected upon the publication of an ongoing long-term observational cohort study 'PROTOCOL' (27).

Are there any contraindications to FP?

Congenital and acquired cardiovascular diseases are directly related to an increased mortality and morbidity incidence in patients with TS (69, 70). Congenital heart defects affect 20–50% of patients with TS. Bicuspid aortic valve (BAV) is observed in approximately 30% of cases, while coarctation of the aorta (CoA) in 7–18% of cases (70). Aortic dilatation occurs in 20–25% of patients with TS, and it can lead to aortic dissection (AoD) which is the most serious cardiovascular complication, with mortality ratio reaching 58% (71, 72). Aortic dilatation tends to

occur more frequently in patients with structural heart anomalies (BAV, CoA, and elongated transverse aorta) and hypertension (73). Due to reduced final height in TS women, aortic diameter should be corrected by body surface area. TS-specific Z-score of <2.5 for patients younger than 16 years old or aortic size index (ASI) <2.0 cm/m² in patients older than 16 years old is considered normal aortic size (2).

A special condition affecting the development of severe cardiovascular system complications is pregnancy. Current guidelines by Gravholt *et al.* suggest that in case of serious aortic dilatation (an ascending ASI of >2.5 cm/m²) or an ascending ASI 2.0–2.5 cm/m² with associated risk factors for aortic AoD (including BAV, CoA, elongated transverse aorta, and hypertension), ART or spontaneous conception should be avoided (2). Those recommendations are consistent with American Heart Association (AHA) statement from 2018 (74). American Society for Reproductive Medicine states that every significant heart abnormality or ASI > 2 cm/m² is an absolute contraindication to pregnancy (75).

Literature analysis was performed to show the prevalence of AoD in pregnant TS women and describe the characteristics of patients in which AoD occurred. This data can be helpful in determining the eligibility for FP, when the decision about the invasive procedure in very young age should be made after excluding the high risk of pregnancy. Current opinion on pregnancy in TS women is based on the study from 2003. Karnis estimated the prevalence of AoD among pregnant TS women as 2% based on analysis of four cases of AoD in pregnant TS women and results of the survey conducted among ART centre (76). Recent studies reviewed in this article present more optimistic data – only seven cases of AoD were described by five authors. In most of the studies, the prevalence of high-risk pregnancies was not established due to poor rate of cardiac screening before conception (Table 1). Grewal *et al.* described 10 patients (15%) fulfilling the ASRM high-risk pregnancy criteria, with observation of no adverse cardiovascular outcomes reported in this group (77). When analysing the characteristics of pregnant TS women who were diagnosed with AoD (Table 2), it can be seen that dilatation of aorta is not the factor necessary for the occurrence of AoD. Cauldwell *et al.* described two patients with AoD with normal aortic diameter (78). Patient number 2 (Table 2) described by Chevalier *et al.* had no cardiac disturbances despite mild aortic insufficiency described in preconceptional echocardiography; however, the enlargement of aortic root (35 mm) was diagnosed at 6 months of pregnancy (79). Those findings show

that careful cardiac care during pregnancy is necessary even when the pregnancy is not considered high risk for cardiovascular events. Cabanes *et al.* recommend cardiac screening at the end of the first and the second trimester and every month of the third trimester. The heart MRI should be performed in case of $>10\%$ increase in aortic diameter. If the aortic dilatation is confirmed, patients should be referred to hospital with access to the team of specialists of medical-surgical cardiology, obstetrics, and neonatal intensive care (57).

In conclusion, isolated heart defects should not be contraindication to FP. Vigilance and immediate reaction when there is a risk of cardiovascular complication is crucial while providing the health care of pregnant TS woman.

Conclusions

Eligibility for FP techniques should be established based on multiple factors. Primarily, ovarian reserve markers, and cardiovascular contraindications to pregnancy should be thoroughly analysed prior to any intervention. Among them there are, however, no unambiguous indicators disqualifying the patient from FP. Therefore, the decision should be made weighing the risks of invasive FP techniques and ethical concerns connected with patient's age, with the chance of successfully preserving the reproductive potential. More evidence is thus needed to properly assess those odds and introduce FP in patients with TS into the standard practice.

Declaration of interest

The authors declare that there is no conflict of interest that could be perceived as prejudicing the impartiality of the research reported.

Funding

This work did not receive any specific grant from any funding agency in the public, commercial, or not-for-profit sector.

Author contribution statement

M W, J G, Z N, and A G performed literature searches, analysed the database, and wrote the manuscript.

References

- 1 Stochholm K, Juul S, Juel K, Naeraa RW & Gravholt CH. Prevalence, incidence, diagnostic delay, and mortality in Turner syndrome. *Journal of Clinical Endocrinology and Metabolism* 2006 **91** 3897–3902. (<https://doi.org/10.1210/jc.2006-0558>)

- 2 Gravholt CH, Andersen NH, Conway GS, Dekkers OM, Geffner ME, Klein KO, Lin AE, Mauras N, Quigley CA, Rubin K, *et al.* Clinical practice guidelines for the care of girls and women with Turner syndrome: proceedings from the 2016 Cincinnati International Turner Syndrome Meeting. *European Journal of Endocrinology* 2017 **177** G1–G70. (<https://doi.org/10.1530/EJE-17-0430>)
- 3 Sylvé L, Magnusson C, Hagenfeldt K & von Schoultz B. Life with Turner's syndrome – a psychosocial report from 22 middle-aged women. *Acta Endocrinologica* 1993 **129** 188–194. (<https://doi.org/10.1530/acta.0.1290188>)
- 4 Bernard V, Donadille B, Zenaty D, Courtillot C, Salenave S, Brac de la Perrière A, Albarel F, Fèvre A, Kerlan V, Brue T, *et al.* Spontaneous fertility and pregnancy outcomes amongst 480 women with Turner syndrome. *Human Reproduction* 2016 **31** 782–788. (<https://doi.org/10.1093/humrep/dew012>)
- 5 Bryman I, Sylvé L, Berntorp K, Innala E, Bergström I, Hanson C, Oxholm M & Landin-Wilhelmsen K. Pregnancy rate and outcome in Swedish women with Turner syndrome. *Fertility and Sterility* 2011 **95** 2507–2510. (<https://doi.org/10.1016/j.fertnstert.2010.12.039>)
- 6 Oktay K & Bedoschi G. Fertility preservation in girls with Turner syndrome: limitations, current success and future prospects. *Fertility and Sterility* 2019 **111** 1124–1126. (<https://doi.org/10.1016/j.fertnstert.2019.03.018>)
- 7 Oktay K, Bedoschi G, Berkowitz K, Bronson R, Kashani B, McGovern P, Pal L, Quinn G & Rubin K. Fertility preservation in females with Turner syndrome: a comprehensive review and practical guidelines. *Journal of Pediatric & Adolescent Gynecology* 2017 **29** 409–416. (<https://doi.org/10.1016/j.jpjag.2015.10.011>)
- 8 Aso K, Koto S, Higuchi A, Ariyasu D, Izawa M, Miyamoto Igaki J & Hasegawa Y. Serum FSH level below 10 mIU/mL at twelve years old is an index of spontaneous and cyclical menstruation in Turner syndrome. *Endocrine Journal* 2010 **57** 909–913. (<https://doi.org/10.1507/endocrj.k10e-092>)
- 9 Grynberg M, Bidet M, Benard J, Poulain M, Sonigo C, Cédric-Durnerin I & Polak M. Fertility preservation in Turner syndrome. *Fertility and Sterility* 2016 **105** 13–19. (<https://doi.org/10.1016/j.fertnstert.2015.11.042>)
- 10 Hreinsson JG, Ojala M, Fridström M, Borgström B, Rasmussen C, Lundqvist M, Tuuri T, Simberg N, Mikkola M, Dunkel L, *et al.* Follicles are found in the ovaries of adolescent girls with Turner's syndrome. *Journal of Clinical Endocrinology and Metabolism* 2002 **87** 3618–3623. (<https://doi.org/10.1210/jcem.87.8.8753>)
- 11 Fitz VW, Law JR & Peavey M. Karyotype is associated with timing of ovarian failure in women with Turner syndrome. *Journal of Pediatric Endocrinology and Metabolism* 2021 **34** 319–323. (<https://doi.org/10.1515/jpem-2020-0304>)
- 12 Noordman ID, van der Velden JA, Timmers HJ, Pienkowski C, Köhler B, Kempers M, Reisch N, Richter-Unruh A, Arlt W, Nordenström A, *et al.* Karyotype – phenotype associations in patients with Turner syndrome. *Pediatric Endocrinology Reviews* 2019 **16** 431–440. (<https://doi.org/10.17458/per.vol16.2019.nvt.karyotypeturnersyndrome>)
- 13 Borgström B, Hreinsson J, Rasmussen C, Sheikhi M, Fried G, Keros V, Fridström M & Hovatta O. Fertility preservation in girls with Turner syndrome: prognostic signs of the presence of ovarian follicles. *Journal of Clinical Endocrinology and Metabolism* 2009 **94** 74–80. (<https://doi.org/10.1210/jc.2008-0708>)
- 14 Vergier J, Bottin P, Saias J, Reynaud R, Guillemain C & Courbiere B. Fertility preservation in Turner syndrome: karyotype does not predict ovarian response to stimulation. *Clinical Endocrinology* 2019 **91** 646–651. (<https://doi.org/10.1111/cen.14076>)
- 15 Hook EB & Warburton D. Turner syndrome revisited: review of new data supports the hypothesis that all viable 45,X cases are cryptic mosaics with a rescue cell line, implying an origin by mitotic loss. *Human Genetics* 2014 **133** 417–424. (<https://doi.org/10.1007/s00439-014-1420-x>)
- 16 Fernández-García R, García-Doval S, Costoya S & Pásaro E. Analysis of sex chromosome aneuploidy in 41 patients with Turner syndrome: a study of 'hidden' mosaicism. *Clinical Genetics* 2000 **58** 201–208. (<https://doi.org/10.1034/j.1399-0004.2000.580307.x>)
- 17 Nadesapillai S, van der Velden J, Smeets D, van de Zande G, Braat D, Fleischer K & Peek R. Why are some patients with 45,X Turner syndrome fertile? A young girl with classical 45,X Turner syndrome and a cryptic mosaicism in the ovary. *Fertility and Sterility* 2021 **115** 1280–1287. (<https://doi.org/10.1016/j.fertnstert.2020.11.006>)
- 18 Singh RP & Carr DH. The anatomy and histology of XO human embryos and fetuses. *Anatomical Record* 1966 **155** 369–383. (<https://doi.org/10.1002/ar.1091550309>)
- 19 Reynaud K, Cortvrindt R, Verlinde F, De Schepper J, Bourgain C & Smitz J. Number of ovarian follicles in human fetuses with the 45,X karyotype. *Fertility and Sterility* 2004 **81** 1112–1119. (<https://doi.org/10.1016/j.fertnstert.2003.12.011>)
- 20 Speed RM. Oocyte development in XO fetuses of man and mouse: the possible role of heterologous X-chromosome pairing in germ cell survival. *Chromosoma* 1986 **94** 115–124. (<https://doi.org/10.1007/BF00286989>)
- 21 Modi DN, Sane S & Bhartiya D. Accelerated germ cell apoptosis in sex chromosome aneuploid fetal human gonads. *Molecular Human Reproduction* 2003 **9** 219–225. (<https://doi.org/10.1093/molehr/gag031>)
- 22 Carpini S, Carvalho AB, de Lemos-Marini SHV, Guerra-Junior G & Maciel-Guerra AT. FSH may be a useful tool to allow early diagnosis of Turner syndrome. *BMC Endocrine Disorders* 2018 **18** 8. (<https://doi.org/10.1186/s12902-018-0236-4>)
- 23 Hagen CP, Main KM, Kjaergaard S & Juul A. FSH, LH, inhibin B and estradiol levels in Turner syndrome depend on age and karyotype: longitudinal study of 70 Turner girls with or without spontaneous puberty. *Human Reproduction* 2010 **25** 3134–3141. (<https://doi.org/10.1093/humrep/deq291>)
- 24 Conte FA, Grumbach MM & Kaplan SL. A diphasic pattern of gonadotropin secretion in patients with the syndrome of gonadal dysgenesis. *Journal of Clinical Endocrinology and Metabolism* 1975 **40** 670–674. (<https://doi.org/10.1210/jcem-40-4-670>)
- 25 Hankus M, Soltysik K, Szeliga K, Antosz A, Drosdzol-Cop A, Wilk K, Zachurzok A, Malecka-Tendera E & Gawlik AM. Prediction of spontaneous puberty in Turner syndrome based on mid-childhood gonadotropin concentrations, karyotype, and ovary visualization: a longitudinal study. *Hormone Research in Paediatrics* 2018 **89** 90–97. (<https://doi.org/10.1159/000485321>)
- 26 Volodarsky-Perel A, Zajicek M, Shai D, Raanani H, Gruber N, Gideon K & Meirou D. P-449 evaluation of ovarian reserve in female children and adolescents with non-iatrogenic primary ovarian insufficiency to establish criteria for ovarian tissue cryopreservation. *Human Reproduction* 2021 **36** deab130.448. (<https://doi.org/10.1093/humrep/deab130.448>)
- 27 Schleeboom M, van der Velden J, Braat D, Beerendonk I, van Golde R, Peek R & Fleischer K. TurnerFertility trial: PROTOCOL for an observational cohort study to describe the efficacy of ovarian tissue cryopreservation for fertility preservation in females with Turner syndrome. *BMJ Open* 2019 **9** e030855. (<https://doi.org/10.1136/bmjopen-2019-030855>)
- 28 Cornelisse S, Ramos L, Arends B, Brink-van der Vlugt JJ, de Bruin JP, Curfs MH, Derhaag J, van Dongen A, van Echten-Arends J, Groenewoud ER, *et al.* Comparing the cumulative live birth rate of cleavage-stage versus blastocyst-stage embryo transfers between IVF cycles: a study protocol for a multicentre randomised controlled superiority trial (the ToF trial). *BMJ Open* 2021 **11** e042395. (<https://doi.org/10.1136/bmjopen-2020-042395>)
- 29 Kelsey TW, Anderson RA, Wright P, Nelson SM & Wallace WHB. Data-driven assessment of the human ovarian reserve. *Molecular Human Reproduction* 2012 **18** 79–87. (<https://doi.org/10.1093/molehr/gar059>)
- 30 Nardo LG, Christodoulou D, Gould D, Roberts SA, Fitzgerald CT & Laing I. Anti-Müllerian hormone levels and antral follicle count

- in women enrolled in in vitro fertilization cycles: relationship to lifestyle factors, chronological age and reproductive history. *Gynecological Endocrinology* 2007 **23** 486–493. (<https://doi.org/10.1080/09513590701532815>)
- 31 Hagen CP, Mouritsen A, Mieritz MG, Tinggaard J, Wohlfart-Veje C, Fallentin E, Brocks V, Sundberg K, Jensen LN, Anderson RA, *et al.* Circulating AMH reflects ovarian morphology by magnetic resonance imaging and 3D ultrasound in 121 healthy girls. *Journal of Clinical Endocrinology and Metabolism* 2015 **100** 880–890. (<https://doi.org/10.1210/jc.2014-3336>)
 - 32 Abir R, Ben-Aharon I, Garor R, Yaniv I, Ash S, Stemmer SM, Ben-Haroush A, Freud E, Kravarusic D, Sapir O, *et al.* Cryopreservation of in vitro matured oocytes in addition to ovarian tissue freezing for fertility preservation in paediatric female cancer patients before and after cancer therapy. *Human Reproduction* 2016 **31** 750–762. (<https://doi.org/10.1093/humrep/dew007>)
 - 33 Ruan X, Cheng J, Du J, Jin F, Gu M, Li Y, Ju R, Wu Y, Wang H, Yang W, *et al.* Analysis of fertility preservation by ovarian tissue cryopreservation in pediatric children in China. *Frontiers in Endocrinology* 2022 **13** 930786. (<https://doi.org/10.3389/fendo.2022.930786>)
 - 34 von Wolff M, Roumet M, Stute P & Liebenthron J. Serum anti-Müllerian hormone (AMH) concentration has limited prognostic value for density of primordial and primary follicles, questioning it as an accurate parameter for the ovarian reserve. *Maturitas* 2020 **134** 34–40. (<https://doi.org/10.1016/j.maturitas.2020.02.001>)
 - 35 Ruszała A, Wójcik M & Starzyk J. Evaluation of the usefulness of antimüllerian hormone and inhibin B as markers of ovarian activity in patients with Turner syndrome – preliminary results. *Pediatric Endocrinology, Diabetes, and Metabolism* 2020 **26** 84–88. (<https://doi.org/10.5114/pedm.2020.95622>)
 - 36 Hagen CP, Akglaede L, Sørensen K, Main KM, Boas M, Cleemann L, Holm K, Gravholt CH, Andersson AM, Pedersen AT, *et al.* Serum levels of anti-Müllerian hormone as a marker of ovarian function in 926 healthy females from birth to adulthood and in 172 Turner syndrome patients. *Journal of Clinical Endocrinology and Metabolism* 2010 **95** 5003–5010. (<https://doi.org/10.1210/jc.2010-0930>)
 - 37 Nawroth F, Schüring AN & von Wolff M. The indication for fertility preservation in women with Turner syndrome should not only be based on the ovarian reserve but also on the genotype and expected future health status. *Acta Obstetrica et Gynecologica Scandinavica* 2020 **99** 1579–1583. (<https://doi.org/10.1111/aogs.13984>)
 - 38 Welt CK, McNicholl DJ, Taylor AE & Hall JE. Female reproductive aging is marked by decreased secretion of dimeric inhibin. *Journal of Clinical Endocrinology and Metabolism* 1999 **84** 105–111. (<https://doi.org/10.1210/jcem.84.1.5381>)
 - 39 Gravholt CH, Naeraa RW, Andersson AM, Christiansen JS & Skakkebaek NE. Inhibin A and B in adolescents and young adults with Turner's syndrome and no sign of spontaneous puberty. *Human Reproduction* 2002 **17** 2049–2053. (<https://doi.org/10.1093/humrep/17.8.2049>)
 - 40 Rosendahl M, Simonsen MK & Kjer JJ. The influence of unilateral oophorectomy on the age of menopause. *Climacteric* 2017 **20** 540–544. (<https://doi.org/10.1080/13697137.2017.1369512>)
 - 41 Karnis MF. Fertility, pregnancy, and medical management of Turner syndrome in the reproductive years. *Fertility and Sterility* 2012 **98** 787–791. (<https://doi.org/10.1016/j.fertnstert.2012.08.022>)
 - 42 Bouet PE, Godbout A, El Hachem H, Lefebvre M, Bérubé L, Dionne MD, Kamga-Ngande C & Lapensée L. Fertility and pregnancy in Turner syndrome. *Journal of Obstetrics and Gynaecology Canada* 2016 **38** 712–718. (<https://doi.org/10.1016/j.jogc.2016.02.007>)
 - 43 Jeve YB, Gelbaya T & Fatum M. Time to consider ovarian tissue cryopreservation for girls with Turner's syndrome: an opinion paper. *Human Reproduction Open* 2019 **2019** hoz016. (<https://doi.org/10.1093/hropen/hoz016>)
 - 44 La A & Mastellari E. Fertility preservation for genetic diseases leading to premature ovarian insufficiency (POI). *Journal of Assisted Reproduction and Genetics* 2021 **38** 759–777. (<https://doi.org/10.1007/s10815-021-02067-7>)
 - 45 Lau NM, Huang JY, MacDonald S, Elizur S, Gidoni Y, Holzer H, Chian RC, Tulandi T & Tan SL. Feasibility of fertility preservation in young females with Turner syndrome. *Reproductive Biomedicine Online* 2009 **18** 290–295. ([https://doi.org/10.1016/s1472-6483\(10\)60268-4](https://doi.org/10.1016/s1472-6483(10)60268-4))
 - 46 Talaulikar VS, Conway GS, Pimblett A & Davies MC. Outcome of ovarian stimulation for oocyte cryopreservation in women with Turner syndrome. *Fertility and Sterility* 2019 **111** 505–509. (<https://doi.org/10.1016/j.fertnstert.2018.11.010>)
 - 47 Viuff M & Gravholt CH. Turner syndrome and fertility. *Annales d'Endocrinologie* 2022 **83** 244–249. (<https://doi.org/10.1016/j.ando.2022.06.001>)
 - 48 Oktay K & Bedoschi G. Oocyte cryopreservation for fertility preservation in postpubertal female children at risk for premature ovarian failure due to accelerated follicle loss in Turner syndrome or cancer treatments. *Journal of Pediatric and Adolescent Gynecology* 2014 **27** 342–346. (<https://doi.org/10.1016/j.jpjg.2014.01.003>)
 - 49 Azem F, Brenner A, Malinger G, Reches A, Many A, Yogev Y & Leventhal Y. Bypassing physiological puberty, a novel procedure of oocyte cryopreservation at age 7: a case report and review of the literature. *Fertility and Sterility* 2020 **114** 374–378. (<https://doi.org/10.1016/j.fertnstert.2020.03.009>)
 - 50 Ye M, Yeh J, Kosteria I & Li L. Progress in fertility preservation strategies in Turner syndrome. *Frontiers of Medicine* 2020 **7** 1–8. (<https://doi.org/10.3389/fmed.2020.00003>)
 - 51 Cobo A & Diaz C. Clinical application of oocyte vitrification: a systematic review and meta-analysis of randomized controlled trials. *Fertility and Sterility* 2011 **96** 277–285. (<https://doi.org/10.1016/j.fertnstert.2011.06.030>)
 - 52 Ito A, Katagiri Y, Tamaki Y, Fukuda Y, Oji A & Morita M. DuoStim: a new option for fertility preservation for a woman with Turner syndrome. *Gynecological Endocrinology* 2020 **36** 1144–1148. (<https://doi.org/10.1080/09513590.2020.1822805>)
 - 53 Ao A, Jin S, Rao D, Son WY, Chian RC & Tan SL. First successful pregnancy outcome after preimplantation genetic diagnosis for aneuploidy screening in embryos generated from natural-cycle in vitro fertilization combined with an in vitro maturation procedure. *Fertility and Sterility* 2006 **85** 1510.e9–1510.e11. (<https://doi.org/10.1016/j.fertnstert.2005.10.066>)
 - 54 Chen C. Pregnancy after human oocyte cryopreservation. *Lancet* 1986 **1** 884–886. ([https://doi.org/10.1016/s0140-6736\(86\)90989-x](https://doi.org/10.1016/s0140-6736(86)90989-x))
 - 55 Strypstein L, Van Moer E, Nekkebroeck J, Segers I, Tournaye H, Demeestere I, Dolmans MM, Verpoest W & De Vos M. First live birth after fertility preservation using vitrification of oocytes in a woman with mosaic Turner syndrome. *Journal of Assisted Reproduction and Genetics* 2022 **39** 543–549. (<https://doi.org/10.1007/s10815-022-02420-4>)
 - 56 Bedoschi G & Oktay K. Current approach to fertility preservation by embryo cryopreservation. *Fertility and Sterility* 2013 **99** 1496–1502. (<https://doi.org/10.1016/j.fertnstert.2013.03.020>)
 - 57 Cabanes L, Chalas C, Christin-Maitre S, Donadille B, Felten ML, Gaxotte V, Jondeau G, Lansac E, Lansac J, Letur H, *et al.* Turner syndrome and pregnancy: clinical practice. Recommendations for the management of patients with Turner syndrome before and during pregnancy. *European Journal of Obstetrics, Gynecology, and Reproductive Biology* 2010 **152** 18–24. (<https://doi.org/10.1016/j.ejogrb.2010.05.019>)
 - 58 El-shawarby SA, Sharif F, Conway G, Serhal P & Davies M. Oocyte cryopreservation after controlled ovarian hyperstimulation in mosaic Turner syndrome: another fertility preservation option in a dedicated UK clinic. *BJOG* 2010 **117** 234–237. (<https://doi.org/10.1111/j.1471-0528.2009.02422.x>)
 - 59 Schleedoorn MJ, Mulder BH, Braat DDM, Beerendonk CCM, Peek R, Nelen WLDM, Van Leeuwen E, Van der Velden AAEM, Fleischer K & on behalf of the Turner Fertility Expert Panel. International consensus: ovarian tissue cryopreservation in young Turner syndrome patients:

- outcomes of an ethical Delphi study including 55 experts from 16 different countries. *Human Reproduction* 2020 **35** 1061–1072. (<https://doi.org/10.1093/humrep/deaa007>)
- 60 Grynberg M, Poulain M, Sebag-Peyrelevade S, le Parco S, Fanchin R & Frydman N. Ovarian tissue and follicle transplantation as an option for fertility preservation. *Fertility and Sterility* 2012 **97** 1260–1268. (<https://doi.org/10.1016/j.fertnstert.2012.04.042>)
- 61 Oktay K, Taylan E, Kawahara T & Cillo GM. Robot-assisted orthotopic and heterotopic ovarian tissue transplantation techniques: surgical advances since our first success in 2000. *Fertility and Sterility* 2019 **111** 604–606. (<https://doi.org/10.1016/j.fertnstert.2018.11.042>)
- 62 Revel A, Revel-Vilk S, Aizenman E, Porat-Katz A, Safran A, Ben-Meir A, Weintraub M, Shapira M, Achache H & Laufer N. At what age can human oocytes be obtained? *Fertility and Sterility* 2009 **92** 458–463. (<https://doi.org/10.1016/j.fertnstert.2008.07.013>)
- 63 Revel A, Koler M, Simon A, Lewin A, Laufer N & Safran A. Oocyte collection during cryopreservation of the ovarian cortex. *Fertility and Sterility* 2003 **79** 1237–1239. ([https://doi.org/10.1016/s0015-0282\(02\)04963-4](https://doi.org/10.1016/s0015-0282(02)04963-4))
- 64 Dath C, Dethy A, Van Langendonck A, Van Eyck AS, Amorim CA, Luyckx V, Donnez J & Dolmans MM. Endothelial cells are essential for ovarian stromal tissue restructuring after xenotransplantation of isolated ovarian stromal cells. *Human Reproduction* 2011 **26** 1431–1439. (<https://doi.org/10.1093/humrep/der073>)
- 65 Soleimani R, Heytens E & Oktay K. Enhancement of neoangiogenesis and follicle survival by sphingosine-1-phosphate in human ovarian tissue xenotransplants. *PLoS ONE* 2011 **6** e19475. (<https://doi.org/10.1371/journal.pone.0019475>)
- 66 Huang JY, Tulandi T, Holzer H, Lau NM, Macdonald S, Tan SL & Chian RC. Cryopreservation of ovarian tissue and in vitro matured oocytes in a female with mosaic Turner syndrome: case report. *Human Reproduction* 2008 **23** 336–339. (<https://doi.org/10.1093/humrep/dem307>)
- 67 Mamsen LS, Charkiewicz K, Anderson RA, Telfer EE, McLaughlin M, Kelsey TW, Kristensen SG, Gook DA, Ernst E & Andersen CY. Characterization of follicles in girls and young women with Turner syndrome who underwent ovarian tissue cryopreservation. *Fertility and Sterility* 2019 **111** 1217.e3–1225.e3. (<https://doi.org/10.1016/j.fertnstert.2019.02.003>)
- 68 Pacheco F & Oktay K. Current success and efficiency of autologous ovarian transplantation: a meta-analysis. *Reproductive Sciences* 2017 **24** 1111–1120. (<https://doi.org/10.1177/1933719117702251>)
- 69 Schoemaker MJ, Swerdlow AJ, Higgins CD, Wright AE, Jacobs PA & United Kingdom Clinical Cytogenetics Group. Mortality in women with Turner syndrome in Great Britain: a national cohort study. *Journal of Clinical Endocrinology and Metabolism* 2008 **93** 4735–4742. (<https://doi.org/10.1210/jc.2008-1049>)
- 70 Fuchs MM, Attenhofer Jost C, Babovic-Vuksanovic D, Connolly HM & Egbe A. Long-term outcomes in patients with Turner syndrome: a 68-year follow-up. *Journal of the American Heart Association* 2019 **8** e011501. (<https://doi.org/10.1161/JAHA.118.011501>)
- 71 Carlson M & Silberbach M. Dissection of the aorta in Turner syndrome: two cases and review of 85 cases in the literature. *Journal of Medical Genetics* 2007 **44** 745–749. (<https://doi.org/10.1136/jmg.2007.052019>)
- 72 Duijnhouwer AL, Bons LR, Timmers HJLM, van Kimmenade RRL, Snoeren M, Timmermans J, van den Hoven AT, Kempers M, van Dijk APJ, Fleischer K, *et al.* Aortic dilatation and outcome in women with Turner syndrome. *Heart* 2019 **105** 693–700. (<https://doi.org/10.1136/heartjnl-2018-313716>)
- 73 Hjerrild BE, Mortensen KH, Sørensen KE, Pedersen EM, Andersen NH, Lundorf E, Hansen KW, Hørlyck A, Hager A, Christiansen JS, *et al.* Thoracic aortopathy in Turner syndrome and the influence of bicuspid aortic valves and blood pressure: a CMR study. *Journal of Cardiovascular Magnetic Resonance* 2010 **12** 12. (<https://doi.org/10.1186/1532-429X-12-12>)
- 74 Silberbach M, Roos-Hesselink JW, Andersen NH, Braverman AC, Brown N, Collins RT, De Backer J, Eagle KA, Hiratzka LF, Johnson Jr WH, *et al.* Cardiovascular health in Turner syndrome: a scientific statement from the American Heart Association. *Circulation: Genomic and Precision Medicine* 2018 **11** e000048. (<https://doi.org/10.1161/HCG.0000000000000048>)
- 75 Practice Committee of American Society for Reproductive Medicine. Increased maternal cardiovascular mortality associated with pregnancy in women with Turner syndrome. *Fertility and Sterility* 2012 **97** 282–284. (<https://doi.org/10.1016/j.fertnstert.2011.11.049>)
- 76 Karnis MF, Zimon AE, Lalwani SI, Timmreck LS, Klipstein S & Reindollar RH. Risk of death in pregnancy achieved through oocyte donation in patients with Turner syndrome: a national survey. *Fertility and Sterility* 2003 **80** 498–501. ([https://doi.org/10.1016/s0015-0282\(03\)00974-9](https://doi.org/10.1016/s0015-0282(03)00974-9))
- 77 Grewal J, Valente AM, Egbe AC, Wu FM, Krieger EV, Sybert VP, van Hagen IM, Beauchesne LM, Rodriguez FH, Broberg CS, *et al.* Cardiovascular outcomes of pregnancy in Turner syndrome. *Heart* 2021 **107** 61–66. (<https://doi.org/10.1136/heartjnl-2020-316719>)
- 78 Cauldwell M, Steer PJ, Adamson D, Alexander C, Allen L, Bhagra C, Bolger A, Bonner S, Calanchini M, Carroll A, *et al.* Pregnancies in women with Turner syndrome: a retrospective multicentre UK study. *BJOG* 2022 **129** 796–803. (<https://doi.org/10.1111/1471-0528.17025>)
- 79 Chevalier N, Lelannou D, Ohl J, Cornet D & Papaxanthos-roche A. Materno-fetal cardiovascular complications in Turner syndrome after oocyte donation: insufficient prepregnancy screening and pregnancy follow-up are associated with poor outcome. *Journal of Clinical Endocrinology and Metabolism* 2011 **96** 260–267. (<https://doi.org/10.1210/jc.2010-0925>)
- 80 Calanchini M, Aye CYL, Phil D & Orchard E. Fertility issues and pregnancy outcomes in Turner syndrome. *Fertility and Sterility* 2021 **114** 144–154. (<https://doi.org/10.1016/j.fertnstert.2020.03.002>)
- 81 Kooijman SS, Duijnhouwer AL, Van KRRJ, Van DAPJ, Hink E & Boer M De. Influence of pregnancy on aortic diameter in women With the Turner syndrome. *American Journal of Cardiology* 2020 **140** 122–127. (<https://doi.org/10.1016/j.amjcard.2020.10.047>)
- 82 Cadoret F, Parinaud J, Bettiol C, Pienkowski C, Letur H, Ohl J, Sentilhes L, Papaxanthos A, Winer N, d'Argent ME, *et al.* Pregnancy outcome in Turner syndrome: a French multi-center study after the 2009 guidelines. *European Journal of Obstetrics and Gynecology and Reproductive Biology* 2018 **229** 20–25. (<https://doi.org/10.1016/j.ejogrb.2018.08.005>)
- 83 Obata S, Tsuburai T, Shindo R, Aoki S, Miyagi E & Sakakibara H. Current situation and outcomes of pregnancy in women with Turner syndrome in Japan. *Journal of Obstetrics and Gynaecology Research* 2020 **46** 1728–1734. (<https://doi.org/10.1111/jog.14352>)
- 84 Hadnott TN, Gould HN, Gharib AM & Bondy CA. Outcomes of spontaneous and assisted pregnancies in Turner syndrome: the U.S. National Institutes of Health experience. *Fertility and Sterility* 2011 **95** 2251–2256. (<https://doi.org/10.1016/j.fertnstert.2011.03.085>)
- 85 Mercadal BA, Imbert R, Demeestere I, Englert Y & Delbaere A. Pregnancy outcome after oocyte donation in patients with Turner's syndrome and partial X monosomy. *Human Reproduction* 2011 **26** 2061–2068. (<https://doi.org/10.1093/humrep/der166>)
- 86 Do E, Ceylan Y, Ulak E, Özdamar Ö & Çal E. Reproductive and obstetric outcomes in mosaic Turner's syndrome: a cross-sectional study and review of the literature. *Reproductive Biology and Endocrinology* 2015 **13** 1–7. (<https://doi.org/10.1186/s12958-015-0055-7>)
- 87 Deligeorgiou E, Stergioti E, Dimopoulos KD, Karountzos V & Prapas Y. Pregnancy outcome after oocyte donation in patients with Turner's syndrome: clinical experience and management. *Journal of Obstetrics and Gynaecology* 2016 **36** 504–507. (<https://doi.org/10.3109/1443615.2015.1103714>)
- 88 Hagman A, Loft A, Wennerholm UB, Pinborg A, Bergh C, Aittomäki K, Nygren KG, Bente Romundstad L, Hazekamp J & Söderström-Anttila V. Obstetric and neonatal outcome after oocyte donation in 106 women

- with Turner syndrome: a Nordic cohort study. *Human Reproduction* 2013 **28** 1598–1609. (<https://doi.org/10.1093/humrep/det082>)
- 89 Hagman A, Källén K, Barrenäs ML, Landin-Wilhelmsen K, Hanson C, Bryman I & Wennerholm UB. Obstetric outcomes in women with turner karyotype. *Journal of Clinical Endocrinology and Metabolism* 2011 **96** 3475–3482. (<https://doi.org/10.1210/jc.2011-1421>)
- 90 Bodri D, Vernaeve V, Figueras F, Vidal R, Guillén JJ & Coll O. Oocyte donation in patients with Turner's syndrome: a successful technique but with an accompanying high risk of hypertensive disorders during pregnancy. *Human Reproduction* 2006 **21** 829–832. (<https://doi.org/10.1093/humrep/dei396>)
- 91 Giles J, Meseguer M, Mercader A, Rubio C, Alegre L, Vidal C, Trabalón M & Bosch E. Preimplantation genetic testing for aneuploidy in patients with partial X monosomy using their own oocytes: is this a suitable indication? *Fertility and Sterility* 2020 **114** 346–353. (<https://doi.org/10.1016/j.fertnstert.2020.04.003>)

Received in final form 26 September 2022

Accepted 3 October 2022

Accepted Manuscript published online 3 October 2022