

RESEARCH

Peptide receptor radionuclide therapy for aggressive pituitary tumors: a monocentric experience

G Giuffrida^{1,2}, F Ferrau^{1,3}, R Laudicella^{4,5}, O R Cotta³, E Messina¹, F Granata^{5,6}, F F Angileri^{5,7}, A Vento^{4,5}, A Alibrandi⁸, S Baldari^{4,5} and S Cannavò^{1,2,3}

¹Endocrine Unit of University Hospital 'AOU Policlinico G. Martino', Messina, Italy

²PhD School of Clinical and Experimental Biomedical Sciences, University of Messina, Messina, Sicily, Italy

³Department of Human Pathology 'G. Barresi', University of Messina, Messina, Sicily, Italy

⁴Nuclear Medicine Unit of University Hospital 'AOU Policlinico G. Martino', Messina, Italy

⁵Department of Biomorphology, University of Messina, Messina, Sicily, Italy

⁶Neuroradiology Unit of University Hospital 'AOU Policlinico G. Martino', Messina, Italy

⁷Neurosurgery Unit of University Hospital 'AOU Policlinico G. Martino', Messina, Italy

⁸Department of Economics, University of Messina, Messina, Sicily, Italy

Correspondence should be addressed to F Ferrau: francesco.ferrau1@gmail.com

Abstract

In aggressive pituitary tumors (PT) showing local invasion or growth/recurrence despite multimodal conventional treatment, temozolomide (TMZ) is considered a further therapeutic option, while little data are available on peptide receptor radionuclide therapy (PRRT). We analyzed PRRT effectiveness, safety and long-term outcome in three patients with aggressive PT, also reviewing the current literature. Patient #1 (F, giant prolactinoma) received five cycles (total dose 37 GBq) of ¹¹¹In-DTPA-octreotide over 23 months, after unsuccessful surgery and long-term dopamine-agonist treatment. Patient #2 (M, giant prolactinoma) underwent two cycles (12.6 GBq) of ¹⁷⁷Lu-DOTATOC after multiple surgeries, radiosurgery and TMZ. In patient #3 (F, non-functioning PT), five cycles (29.8 GBq) of ¹⁷⁷Lu-DOTATOC followed five surgeries, radiotherapy and TMZ. Eleven more cases of PRRT-treated aggressive PT emerged from literature. Patient #1 showed tumor shrinkage and visual/neurological amelioration over 8-year follow-up, while the other PTs continued to grow causing blindness and neuro-cognitive disorders (patient #2) or monolateral amaurosis (patient #3). No adverse effects were reported. Including the patients from literature, 4/13 presented tumor shrinkage and clinical/biochemical improvement after PRRT. Response did not correlate with patients' gender or age, neither with used radionuclide/peptide, but PRRT failure was significantly associated with previous TMZ treatment. Overall, adverse effects occurred only in two patients. PRRT was successful in 1/3 of patients with aggressive PT, and in 4/5 of those not previously treated with TMZ, representing a safe option after unsuccessful multimodal treatment. However, at present, considering the few data, PRRT should be considered only in an experimental setting.

Key Words

- ▶ pituitary tumors
- ▶ aggressive pituitary adenomas
- ▶ peptide receptor radionuclide therapy
- ▶ PRRT

Endocrine Connections
(2019) **8**, 528–535

Introduction

Pituitary tumors (PT) are generally benign and slow growing, but in some cases, they can present with the invasion of dura, bone or surrounding structures in the absence of malignant features. In these cases,

they are defined as 'invasive' or 'aggressive' (1). Moreover, the term 'giant' adenoma is usually applied to those tumors exceeding 40 mm in maximum diameter (2).

In PT patients, multimodal treatment, including neurosurgery, drugs and radiotherapy, is generally effective in reducing tumor volume and controlling hormonal hypersecretion, if present (3). Nevertheless, aggressive PT can be characterized by rapid growth, resistance and/or recurrence despite conventional treatments, making their management extremely challenging (4, 5, 6, 7). According to the latest guidelines, temozolomide (TMZ) can be an option after failure of standard therapies in patients with aggressive PT, while very little data are available on alternative approaches such as peptide receptor radionuclide therapy (PRRT) (7). The expression of different subtypes of somatostatin receptors (SSTR, mainly 1, 2 and 5 subtype) on PT cells constitute the pathophysiological basis of their treatment with first generation (octreotide, lanreotide) and second generation (pasireotide) somatostatin analogs (SSa), and the rationale of the use of radiolabeled-SSa for diagnostic imaging and PRRT (^{111}In -pentetreotide, ^{177}Lu -DOTA, ^{90}Y -DOTA, ^{68}Ga -DOTA) (8, 9).

Herein we report on the effectiveness, safety and long-term outcome of PRRT in three patients (2 F, 1 M) with aggressive giant PT treated by our group, also reviewing the little data available in literature about this therapeutic option.

Patients and methods

Between 2009 and 2015, three patients with giant aggressive PT have been treated with PRRT in our university hospital, with an interval of 6–9 weeks between each administration, according to a well-established clinical protocol (10). The study has been approved by the Local Ethical Committee of Messina. The first patient (female, 58 years old), with giant prolactin (PRL)-secreting pituitary adenoma (prolactinoma), received five cycles of ^{111}In -DTPA-octreotide (total activity 37 GBq) from July 2009 to June 2011. Short-term effectiveness, assessed after the first four cycles of this treatment, has been previously reported (11). Here, we show long-term efficacy and safety during the following 7 years. The second patient (male, 54 years old), affected by a giant prolactinoma too, underwent two cycles of PRRT with ^{177}Lu -DOTATOC (total activity 12.6 GBq) in 2015. In the same year, a third case (woman, 53 years old) with a giant non-functioning PT (NFPT) was treated with ^{177}Lu -DOTATOC (five cycles, total activity 29.8 GBq). Some data of these two patients were summarily presented in a previous study (6). In all cases, tumor expression of somatostatin receptors type 2

(SSTR-2) was preliminarily demonstrated by SSTR-scintigraphic imaging with ^{111}In -pentetreotide (Octreoscan) and the treatment options were discussed at our institution's tumor board and approved by the local ethical committee. Each patient (or the daughter, for the first patient who was unconscious at entry) gave written informed consent for treatment. Laboratory investigations were performed before PRRT to confirm that hematologic, renal and hepatic function were adequate for this treatment. Patients were admitted into a dedicated in-patient radioisotope treatment room. Radionuclides were obtained commercially (^{111}In -DTPA-octreotide was provided by Mallinckrodt Medical of Petten, The Netherlands; Perkin Elmer, USA, provided ^{177}Lu -DOTATOC) and re-constituted in-house. PRRT was performed as previously described for gastro-entero-pancreatic (GEP)NETs (12). The intention of treatment was to administer a total activity of 37 GBq of ^{111}In -DTPA-octreotide or of 30 GBq of ^{177}Lu -DOTATOC. Intravenous infusion of aminoacids in 1L of saline solution 0.9% in 4h was performed at any cycle of PRRT in order to reduce tubular peptide uptake and minimize renal damage. Intravenous dexamethasone (8 mg/2 mL for 2 days) was previously administered to reduce/contrast nausea or axial edema. Planned treatment was based on five cycles separated by 8–10 weeks. Full blood count was monitored once every 2 weeks up to 2 months after each PRRT cycle thus excluding any eventual myelosuppressive events. All patients underwent a brain magnetic resonance imaging (MRI) scan before PRRT and after 2, 6, 12, 18 and 24 months from PRRT and every year thereafter.

In addition, we systematically searched for prospective or retrospective studies or case reports of patients affected by pituitary masses and treated with PRRT, cited in PubMed until 2018. The descriptors 'pituitary tumor', 'PRRT', 'peptide receptor radionuclide therapy' were combined with the Boolean operators 'AND' and 'OR', to build the search strategies. By this approach, we found 12 more cases presented in 7 scientific papers.

Results

Patient #1

In this patient, macroprolactinoma was diagnosed when she was 42 years old and trans-sphenoidal surgery was performed after few months of ineffective high-dose cabergoline treatment. At the age of 55 years, serum PRL concentrations remarkably increased and tumor remnant dramatically grew, despite cabergoline administration.

Radiotherapy was started and early interrupted due to a rapid worsening of clinical conditions. After the demonstration of SSTR-2 expression in the tumor by Octreoscan, a single i.m. injection of octreotide LAR 30mg had been administered, but PT size and PRL levels continued to grow up. When referred to our university hospital, the patient showed critical neurological impairment and was not collaborative. Incomplete ptosis of left eyelid and left oculomotor nerve palsy with mydriasis were evident. PRRT was followed by progressive shrinkage of the pituitary mass, from 63 mL (before treatment) to 3.1 mL at last MRI scan (Fig. 1). The biochemical evaluation showed a dramatic decrease of serum PRL values (350.000 U/L before PRRT vs 30.310 U/L at the last evaluation; n.v. 102–496 U/L). Treatment with cabergoline, administered at the dose of 0.5 mg daily before PRRT, was continued at the same dose until the last follow-up visit. Central hypothyroidism and hypogonadism were present before PRRT, and the residual pituitary function did not change over the following years. Computed perimetry, not assessable at admission, showed temporal anopsy in the right eye and nasal anopsy in the left one at last evaluation. Consciousness status and general clinical conditions improved progressively during the first months of treatment, and she regained

full autonomy thereafter. PRRT was well tolerated in the absence of any treatment-related adverse events during follow-up.

Patient #2

In the second case, a giant prolactinoma was diagnosed in 2008. Treatment with cabergoline, three trans-sphenoidal approaches and hypo-fractionated radiosurgery were not able to control tumor progression. Panhypopituitarism had occurred after radiosurgery. In 2015, he began PRRT but a dramatic increase in tumor size (from 20.2 to 83.6 mL), impairment of visual acuity and worsening of clinical conditions occurred after the second cycle of treatment. For this reason, this therapy was withdrawn and the patient was treated with TMZ and cyclophosphamide, but without any benefit. At present, the patient is still alive but blind, and he complains of gait difficulties and temporo-spatial disorientation. Moreover, his relatives report that the patient developed behavior disturbances.

Patient #3

In the third case, a giant NFPT was diagnosed in 2006. The patient underwent five trans-sphenoidal approaches,

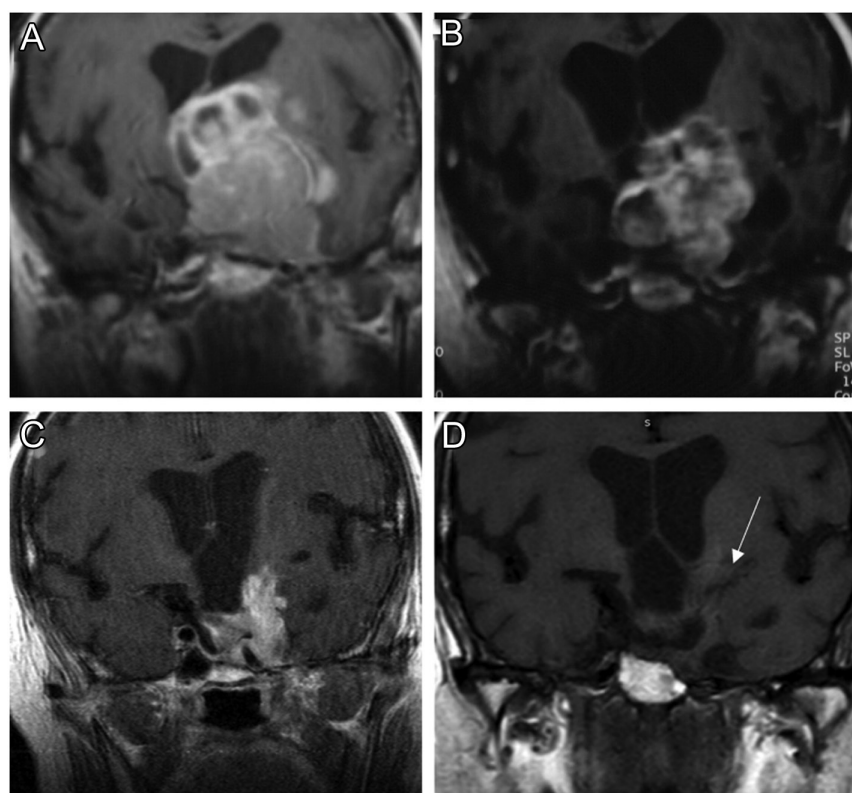


Figure 1

Coronal T1-weighted magnetic resonance imaging (MRI) images showing tumor shrinkage in patient #1: before (A; in 2009), during (B; in 2010), 1 year after (C; in 2012) and 7 years after PRRT (D; in 2016; white arrow: tumor remnant).

fractionated radiotherapy and TMZ treatment before 2015, when she was referred to the multidisciplinary team of our university hospital for PRRT. At admission, panhypopituitarism was present. Neuro-ophthalmological examination demonstrated near complete blindness in the right eye and hemianopsia in the left one. Pituitary MRI performed 6 and 12 months after PRRT showed a significant increase in tumor size (from 7.7 mL to 14.1 mL). Further visual field examinations demonstrated a progressive loss of vision in the left eye. PRRT-related adverse events were not reported during the following 3 years.

Review of literature

Until now, extensive data about effectiveness and safety of PRRT are reported in literature for other nine patients with pituitary carcinomas or aggressive adenomas (13, 14, 15, 16, 17). Three patients affected by pituitary carcinoma were treated with ^{90}Y -DOTATOC (2 cycles), ^{90}Y -DOTATATE or ^{177}Lu -DOTATATE (four cycles), respectively (13, 14, 16). The first one was affected by Nelson syndrome, the second by acromegaly and the third by NFPT. Tumor progression was stopped only in the NFPT patient, who was followed up over 40 months (14). Out of six patients with aggressive pituitary adenomas, two were treated with ^{177}Lu -DOTATATE (one and two cycles, respectively), one with ^{90}Y -DOTATATE (four cycles), one with ^{177}Lu -DOTATOC (three cycles), one with ^{177}Lu -OCTREOTATE and one with ^{68}Ga -DOTATATE (14, 15, 16, 17). Out of them, two were affected by acromegaly, two by NFPTs, one by a prolactinoma and one by a silent ACTH-secreting tumor. Tumor shrinkage and biochemical or clinical improvement were reported in an acromegalic and in a NFPT patient, followed-up over 1 and 8 years post-PRRT, respectively (15, 17). In addition, Lasolle *et al.* reported very few data about completed or ongoing ^{177}Lu -DOTATOC treatment in other two patients with aggressive PTs previously treated with TMZ; nevertheless, tumor progression occurred after PRRT in the first case (18). Finally, a patient with a pituitary metastasis of ileal primary neuroendocrine tumor was effectively treated with ^{90}Y -DOTATOC and ^{177}Lu -DOTATATE by Goglia *et al.* (19). Data of all patients are shown in Table 1 and Fig. 2.

Overall evaluation

On the basis of our experience and of data from literature, PRRT determined the growth arrest/shrinkage of tumor and clinical/biochemical improvement in

4 out of 13 patients with aggressive PT and in the patient with pituitary metastasis (Fig. 2). Response to PRRT was related nor to gender or age of patients, neither to radionuclide or peptide used for treatment, but resistance was significantly associated with previous TMZ treatment (χ^2 : 9.24; $P < 0.002$). Indeed, PRRT was unsuccessful in all the patients previously treated with TMZ, while it was effective in four out of the other five ones (Fig. 2). Accordingly, mean overall survival, after PRRT, in the whole cohort of patients was 50.6 ± 13.0 months, while it was 15.0 ± 5.1 months in patients previously treated with TMZ versus 79.2 ± 15.0 months in those who did not undergo TMZ (Fig. 3).

Overall, PRRT was generally well tolerated and transient anemia and leucopenia occurred only in a responder acromegalic patient (17). Severe adverse events imposed treatment interruption only in a patient with silent ACTH-secreting PT, for the early occurrence of facial pain (14).

Discussion

In this study, we reported about the effects of PRRT in three patients with aggressive PT and reviewed the cases described by other authors. According to the latest guidelines, PRRT can be considered among the therapeutical options of aggressive PT patients when other approaches (surgical reintervention, medical therapies, fractionated or stereotactic radiotherapies, TMZ or other systemic chemotherapies) are not feasible or fail into controlling disease progression (7, 20). Indeed, although ‘cold’ SSAs are sometimes ineffective because of post-receptor resistance, the expression of SSRTs (mainly SSTR-2 and SSTR-5) on PT, demonstrated by functional imaging with Octreoscan or ^{68}Ga -DOTA positron emitting tomography, can allow to introduce beta minus emitters radiopharmaceuticals conjugated to SSa for target therapy (14, 21). PRRT has been introduced in the 1990s for metastatic or inoperable GEP-NETs and bronchial carcinoids. First, ^{111}In -pentetreotide was preferred for its clinical efficacy, related to both the therapeutic Auger-emission and the internal conversion electrons after cellular internalization. Then, more efficient compounds have been introduced, like the high energy beta-emitter ^{90}Y (longer range in soft tissues) and the beta and gamma emitter ^{177}Lu (22). Moreover, the more recent chelated analog [DOTA⁰,Tyr³]-octreotate (DOTATATE) has improved the overall effects of PRRT, being characterized by high affinity with SSTR-2 (22, 23, 24). However, in our study, responsiveness to PRRT is

Table 1 Clinical characteristics, treatment modalities and response to peptide receptor radionuclide therapy (PRRT) in the cases reported in literature and data from our three cases.

#	Adenoma type	Reference nr.	Year of publication	Data of treatment	Radioradiopharmaceutical	Cycles	Total activity (GBq)	Volume response	Biochemical response	Clinical response	PFS after PRRT (months)	Previous TMZ	Previous RT	Follow-up (months)
1	PRL	Patient #1 [†]	2018	07/2009–06/2011	¹¹¹ In-DTPA-octreotide	5	37	Yes	Yes	Yes	96	No	Partial	96
2	PRL	Patient #2 [‡]	2018	2015	¹⁷⁷ Lu-DOTATOC	2	12.6	No	No	No	4	Yes	Yes	36
3	NFPT	Patient #3 [‡]	2018	2015	¹⁷⁷ Lu-DOTATOC	5	29.8	No	Not evaluable	No	6	Yes	Yes	36
4	ACTH (*)	13	2013	2006	⁹⁰ Y-DOTATOC	2	7.4	No	No	No	–	No	Yes	12
5	NFPT (*)	14	2014	01/2010–01/2011	¹⁷⁷ Lu-DOTATATE	4	7.4	Yes	Not evaluable	Yes	40	No	No	40
6	ACTH atypical	14	2014	10/2011–11/2011	¹⁷⁷ Lu-DOTATATE	1	NA	No	No	No	–	Yes	Yes	2
7	GH-PRL atypical	14	2014	10/2011	¹⁷⁷ Lu-DOTATATE	2	15.3	No	No	No	–	Yes	Yes	13
8	NFPT	15	2014	2005	¹⁷⁷ Lu-DOTATOC	3	22.2	Yes	Not evaluable	Yes	96	No	Yes	96
9	GH (*)	16	2015	NA	⁹⁰ Y-DOTATATE	NA	NA	No	No	No	–	Yes	No	7
10	PRL	16	2015	NA	⁶⁸ Ga-DOTATATE	NA	NA	No	No	No	–	Yes	No	7
11	NFPT	16	2015	NA	¹⁷⁷ Lu-OCTREOTATE	NA	NA	No	Not evaluable	No	–	Yes	No	4
12	GH	17	2016	2015	⁹⁰ Y-DOTATATE	4	14.8	Yes	Partial	NA	12	No	Yes	12
13	Not specified	18	2017	NA	Not specified	NA	NA	No	No	No	–	Yes	No	24
14	Not specified	18	2017	NA	Not specified	NA	NA	Ongoing	Yes	Yes	–	Yes	No	24
15	NET metastasis**	19	2008	NA	⁹⁰ Y-DOTATOC and ¹⁷⁷ Lu-DOTATATE	4	10.9	Yes	Yes	Yes	–	No	No	18

*These three patients were affected by pituitary carcinomas. **The pituitary mass was a metastasis from a primary unknown neuroendocrine tumor (NET), so it is reported at the bottom of the main list above (italics). [†]Data about the short-term effectiveness of PRRT treatment in this case have been reported in a previous study by our group (11). [‡]Data concerning these two patients have been summarized in the study by Priola *et al.* (6).

GBq, giga becquerel; NA, not available; PFS, progression-free survival (from PRRT); RT, radiotherapy; TMZ, temozolomide.

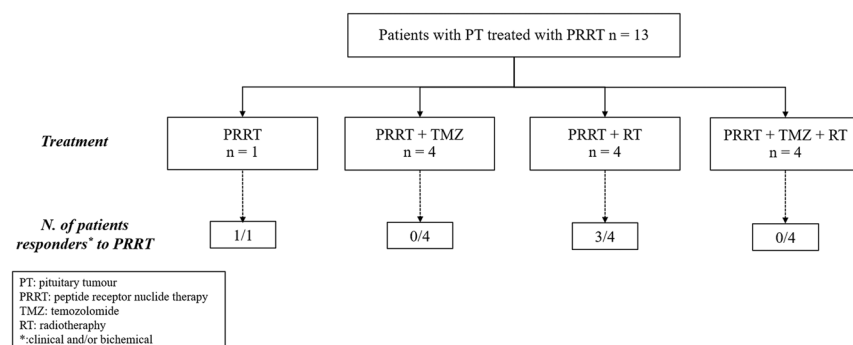


Figure 2

Outcome of PRRT in PT patients according to different treatment strategies.

not associated with the use of a specific radionuclide or peptide. PRRT-related organ radiation exposure is variable, being higher in kidneys and bone marrow. In this context, ^{111}In -DTPA-octreotide demonstrated a shorter tissue penetration of Auger electrons, avoiding damage to surrounding tissues, and therefore, could be more suitable for SNC neoplasms such as aggressive PT. In addition, ^{111}In -DTPA-octreotide is generally well tolerated, with a lower risk of developing severe side effects (25, 26). However, to date, patient #1 is the only published case of PT treated with ^{111}In -DTPA-octreotide. In our case series, one out of three patients experienced a progressive significant PT shrinkage after PRRT with ^{111}In -DTPA-octreotide, over an 8-year follow-up. In the other two patients, tumor progression was documented at the first MRI control. Our data are in accordance with those of literature (6, 7, 14). Overall, PRRT is effective in about one-third of patients affected by aggressive PT, irrespective if they are aggressive adenomas or carcinomas. This rate of responsiveness is not very different from other approaches such as TMZ

or other chemotherapies, largely used in patients with these aggressive tumors (16, 27, 28). On this regard, it is noteworthy that previous TMZ treatment is significantly associated with PRRT resistance. Indeed, PRRT determined tumor shrinkage or arrest of progression in four out of five patients not previously treated with TMZ. At present, the biological mechanism underlying this resistance is unknown and other studies will be useful to confirm this finding and to explain the molecular causes. Conversely, age or gender of patients, as well as radionuclide or peptide used for treatment, are not predictors of PRRT response. In addition, none of our patients experienced PRRT-related side effects, but transient myelosuppression or facial pain occurred in two cases described in the literature (14, 17).

Our study presents some criticisms. It is retrospective, the patients' group is small and treatment protocols are inhomogeneous. In addition, dosimetric evaluation was performed in none of our patients. Only in the study by Maclean *et al.*, an inhomogeneous uptake across the tumor was demonstrated in one out of three patients (14).

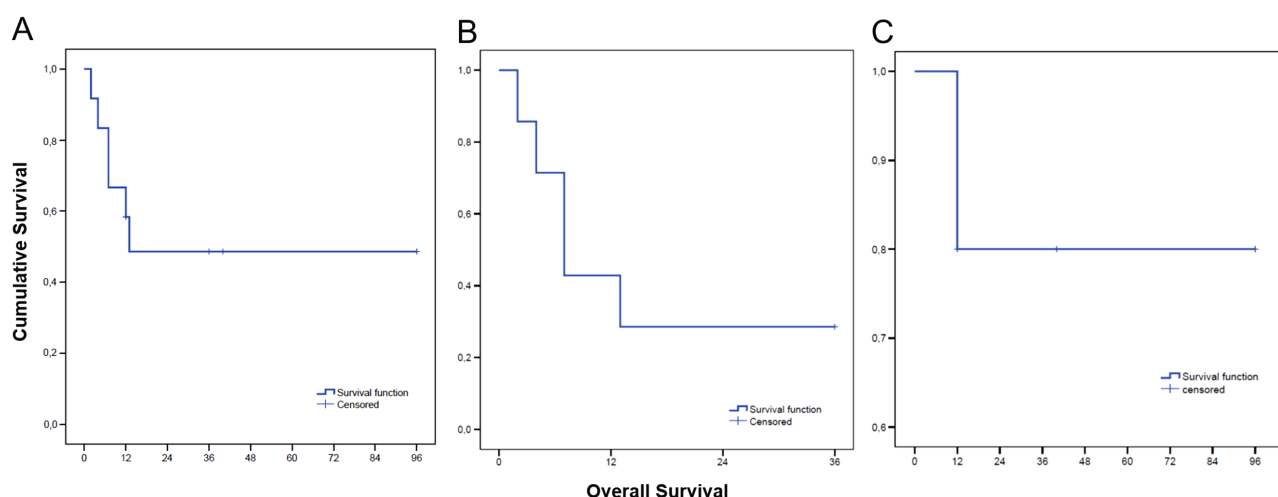


Figure 3

Overall survival in the entire cohort of patients treated with PRRT (A; data available for 12 cases), and in patients treated (B; $n = 7$) or not (C; $n = 5$) with temozolomide before PRRT.

Nevertheless, there are few studies on PRRT in patients with aggressive PT and this approach could be a very useful option when all the other treatments failed to stop tumor progression and clinical impairment.

In conclusion, our study shows that PRRT can induce PT shrinkage and clinical and/or biochemical improvement in one-third of patients with aggressive PT overall, and in 4/5 of those not previously treated with TMZ. At the same time, PRRT is a safe therapeutic option when surgery and radiosurgery have failed to control tumor progression. Nevertheless, the overall efficacy cannot be established on the basis of the few available studies, and the currently available evidence is biased by the inhomogeneous treatment modalities. For this reason, at present, PRRT can be proposed for aggressive PT only in an experimental setting, after all conventional options have been performed.

Declaration of interest

The authors declare that there is no conflict of interest that could be perceived as prejudicing the impartiality of the research reported.

Funding

This study is supported by the grant PRIN 2015 N. 2015ZHKFTA of the Department of Instruction, University and Research of the Italian Government.

References

- Chatzellis E, Alexandraki KI, Androulakis II & Kaltsas G. Aggressive pituitary tumors. *Neuroendocrinology* 2015 **101** 87–104. (<https://doi.org/10.1159/000371806>)
- Mortini P, Barzaghi R, Losa M, Boari N & Giovanelli M. Surgical treatment of giant pituitary adenomas: strategies and results in a series of 95 consecutive patients. *Neurosurgery* 2007 **60** 993–1002; discussion 1003. (<https://doi.org/10.1227/01.NEU.0000255459.14764.BA>)
- Fleseriu M, Hashim IA, Karavitaki N, Melmed S, Murad MH, Salvatori R & Samuels MH. Hormonal replacement in hypopituitarism in adults: an Endocrine Society clinical practice guideline. *Journal of Clinical Endocrinology and Metabolism* 2016 **101** 3888–3921. (<https://doi.org/10.1210/jc.2016-2118>)
- Lloyd RV, Osamura RY, Klöppel G & Rosai J Eds. *WHO Classification of Tumours of Endocrine Organs*, 4th ed. Lyon, France: IARC Press 2017.
- Lopes MBS. The 2017 World Health Organization classification of tumors of the pituitary gland: a summary. *Acta Neuropathologica* 2017 **134** 521–535. (<https://doi.org/10.1007/s00401-017-1769-8>)
- Priola SM, Esposito F, Cannavò S, Conti A, Abbritti RV, Barresi V, Baldari S, Ferraù F, Germanò A, Tomasello F, *et al.* Aggressive pituitary adenomas: the Dark Side of the Moon. *World Neurosurgery* 2017 **97** 140–155. (<https://doi.org/10.1016/j.wneu.2016.09.092>)
- Raverot G, Burman P, McCormack A, Heaney A, Petersenn S, Popovic V, Trouillas J, Dekkers OM & European Society of Endocrinology. European Society of Endocrinology Clinical Practice Guidelines for the management of aggressive pituitary tumours and carcinomas. *European Journal of Endocrinology* 2018 **178** G1–G24. (<https://doi.org/10.1530/EJE-17-0796>)
- Miller GM, Alexander JM, Bikkal HA, Katznelson L, Zervas NT & Klibanski A. Somatostatin receptor subtype gene expression in pituitary adenomas. *Journal of Clinical Endocrinology and Metabolism* 1995 **80** 1386–1392. (<https://doi.org/10.1210/jcem.80.4.7714115>)
- Colao A, Auriemma RS, Lombardi G & Pivonello R. Resistance to somatostatin analogs in acromegaly. *Endocrine Reviews* 2011 **32** 247–271. (<https://doi.org/10.1210/er.2010-0002>)
- Bodei L, Kidd M, Prasad V & Modlin IM. Peptide receptor radionuclide therapy of neuroendocrine tumors. *Frontiers of Hormone Research* 2015 **44** 198–215. (<https://doi.org/10.1159/000402936>)
- Baldari S, Ferraù F, Alafaci C, Herberg A, Granata F, Militano V, Salpietro FM, Trimarchi F & Cannavò S. First demonstration of the effectiveness of peptide receptor radionuclide therapy (PRRT) with ¹¹¹In-DTPA-octreotide in a giant PRL-secreting pituitary adenoma resistant to conventional treatment. *Pituitary* 2012 **15** 57–60. (<https://doi.org/10.1007/s11102-011-0373-5>)
- Kwekkeboom DJ, de Herder WW, Kam BL, van Eijck CH, van Essen M, Kooij PP, Feelders RA, van Aken MO & Krenning EP. Treatment with the radiolabeled somatostatin analog [¹⁷⁷Lu-DOTA 0,Tyr3]octreotate: toxicity, efficacy, and survival. *Journal of Clinical Oncology* 2008 **26** 2124–2130. (<https://doi.org/10.1200/JCO.2007.15.2553>)
- Kovács GL, Góth M, Rotondo F, Scheithauer BW, Carlsen E, Saadia A, Hubina E, Kovács L, Szabolcs I, Nagy P, *et al.* ACTH-secreting Crouke cell carcinoma of the pituitary. *European Journal of Clinical Investigation* 2013 **43** 20–26. (<https://doi.org/10.1111/eci.12010>)
- Maclean J, Aldridge M, Bomanji J, Short S & Fersht N. Peptide receptor radionuclide therapy for aggressive atypical pituitary adenoma/carcinoma: variable clinical response in preliminary evaluation. *Pituitary* 2014 **17** 530–538. (<https://doi.org/10.1007/s11102-013-0540-y>)
- Komor J, Reubi JC & Christ ER. Peptide receptor radionuclide therapy in a patient with disabling non-functioning pituitary adenoma. *Pituitary* 2014 **17** 227–231. (<https://doi.org/10.1007/s11102-013-0494-0>)
- Bengtsson D, Schröder HD, Andersen M, Maiter D, Berinder K, Feldt Rasmussen U, Rasmussen ÅK, Johannsson G, Hoybye C, van der Lely AJ, *et al.* Long-term outcome and MGMT as a predictive marker in 24 patients with atypical pituitary adenomas and pituitary carcinomas given treatment with temozolomide. *Journal of Clinical Endocrinology and Metabolism* 2015 **100** 1689–1698. (<https://doi.org/10.1210/jc.2014-4350>)
- Waligórska-Stachura J, Gut P, Sawicka-Gutaj N, Liebert W, Gryczyńska M, Baszko-Błaszyk D, Blanco-Gangoo AR & Ruchała M. Growth hormone-secreting macroadenoma of the pituitary gland successfully treated with the radiolabeled somatostatin analog ⁹⁰Y-DOTATATE: case report. *Journal of Neurosurgery* 2016 **125** 346–349. (<https://doi.org/10.3171/2015.6.JNS15363>)
- Lasolle H, Cortet C, Castinetti F, Cloix L, Caron P, Delemer B, Desailoud R, Jublanc C, Lebrun-Frenay C, Sadoul JL, *et al.* Temozolomide treatment can improve overall survival in aggressive pituitary tumors and pituitary carcinomas. *European Journal of Endocrinology* 2017 **176** 769–777. (<https://doi.org/10.1530/EJE-16-0979>)
- Goglia U, Ferone D, Sidoti M, Spaziante R, Dadati P, Ravetti JL, Villa G, Bodei L, Paganelli G, Minuto F, *et al.* Treatment of a pituitary metastasis from a neuroendocrine tumour: case report and literature review. *Pituitary* 2008 **11** 93–102. (<https://doi.org/10.1007/s11102-007-0038-6>)
- Even-Zohar N & Greenman Y. Management of NFAs: medical treatment. *Pituitary* 2018 **21** 168–175. (<https://doi.org/10.1007/s11102-018-0865-7>)
- Cuevas-Ramos D & Fleseriu M. Somatostatin receptor ligands and resistance to treatment in pituitary adenomas. *Journal of Molecular*

- Endocrinology* 2014 **52** R223–R240. (<https://doi.org/10.1530/JME-14-0011>)
- 22 de Jong M, Breeman WA, Bernard BF, Bakker WH, Schaar M, van Gameren A, Bugaj JE, Erion J, Schmidt M, Srinivasan A, *et al.* [177Lu-DOTA0,Tyr3]Octreotate for somatostatin receptor-targeted radionuclide therapy. *International Journal of Cancer* 2001 **92** 628–633. ([https://doi.org/10.1002/1097-0215\(20010601\)92:5<628::AID-IJC1244>3.0.CO;2-L](https://doi.org/10.1002/1097-0215(20010601)92:5<628::AID-IJC1244>3.0.CO;2-L))
- 23 Kwekkeboom DJ, Teunissen JJ, Bakker WH, Kooij PP, de Herder WW, Feelders RA, van Eijck CH, Esser JP, Kam BL & Krenning EP. Radiolabeled somatostatin analog [¹⁷⁷Lu-DOTA⁰,Tyr³]octreotate in patients with endocrine gastroenteropancreatic tumors. *Journal of Clinical Oncology* 2005 **23** 2754–2762. (<https://doi.org/10.1200/JCO.2005.08.066>)
- 24 Bodei L, Mueller-Brand J, Baum RP, Pavel ME, Hörsch D, O'Dorisio MS, O'Dorisio TM, Howe JR, Cremonesi M, Kwekkeboom DJ, *et al.* The joint IAEA, EANM, and SNMMI practical guidance on peptide receptor radionuclide therapy (PRRT) in neuroendocrine tumors. *European Journal of Nuclear Medicine and Molecular Imaging* 2013 **40** 800–816. (<https://doi.org/10.1007/s00259-012-2330-6>)
- 25 Kwekkeboom D, Krenning EP & de Jong M. Peptide receptor imaging and therapy. *Journal of Nuclear Medicine* 2000 **41** 1704–1713.
- 26 De Jong M, Breeman WA, Bakker WH, Kooij PP, Bernard BF, Hofland LJ, Visser TJ, Srinivasan A, Schmidt MA, Erion JL, *et al.* Comparison of ¹¹¹In-labeled somatostatin analogues for tumor scintigraphy and radionuclide therapy. *Cancer Research* 1998 **58** 437–441.
- 27 Curtò L, Torre ML, Ferraù F, Pitini V, Altavilla G, Granata F, Longo M, Hofland LJ, Trimarchi F & Cannavò S. Temozolomide-induced shrinkage of a pituitary carcinoma causing Cushing's disease - report of a case and literature review. *ScientificWorldJournal* 2010 **10** 2132–2138. (<https://doi.org/10.1100/tsw.2010.210>)
- 28 Losa M, Bogazzi F, Cannavo S, Ceccato F, Curtò L, De Marinis L, Iacovazzo D, Lombardi G, Mantovani G, Mazza E, *et al.* Temozolomide therapy in patients with aggressive pituitary adenomas or carcinomas. *Journal of Neuro-Oncology* 2016 **126** 519–525. (<https://doi.org/10.1007/s11060-015-1991-y>)

Received in final form 16 March 2019

Accepted 1 April 2019

Accepted Preprint published online 2 April 2019